I INTERNATIONAL CONGRESS ON VETERINARY SCIENCES

GERIATRICS



10-11 April, 2026

Paredes, Portugal

SCIENTIFIC LETTERS SL

BOOK OF ABSTRACTS

Volume 1 Supplement 2 (2026)

ISSN 2795-5117

CESPU University Publishing

https://publicacoes.cespu.pt/index.php/sl

CESPU INSTITUTO UNIVERSITÁRIO DE CIÊNCIAS DA SAÚDE UNIVERSITY INSTITUTE OF HEALTH SCIENCES

CESPU INSTITUTO POLITÉCNICO DE SAÚDE DO NORTE POLYTECHNIC UNIVERSITY OF HEALTH

EDITORIAL COUNCIL

(Scientific Letters [2795-5117])

Hassan Bousbaa, Editor-in-Chief
Joana Barbosa, Copyeditor
Virgínia Gonçalves, Production editor

EDITORIAL OFFICE

CESPU University Publishing
Rua Central de Gandra, 1317
4585-116, Gandra PRD
Portugal

ADMINISTRATIVE EDITOR

Rui Azevedo

DOI: https://doi.org/10.48797/sl.2026.525

For citation purposes, cite each abstract independently as indicated on the abstract page at https://publicacoes.cespu.pt/index.php/sl/article/view/525.

© 2026 by the authors. Abstracts in this book are Open Access and distributed under the Creative Commons Attribution (CC-BY) license, which allows users to download, copy and build upon published articles, as long as the author and publisher are properly credited, which ensures maximum dissemination and a wider impact of our publications.
The book as a whole is distributed by IUCS-CESPU Publishing under the terms and conditions of the Creative Commons license CC-BY.

CESPU
INSTITUTO UNIVERSITÁRIO
DE CIÊNCIAS DA SAÚDE
UNIVERSITY INSTITUTE OF HEALTH SCIENCES

CESPU
INSTITUTO POLITÉCNICO
DE SAÚDE DO NORTE
ESCOLA SUPERIOR DE TECNOLOGIAS DA SAÚDE
DO TÂMEGA E SOUSA

I CONGRESSO INTERNACIONAL DE CIÊNCIAS VETERINÁRIAS

GERIATRIA



CENTRO CULTURAL DE PAREDES

10/11 ABRIL '26

PÚBLICO-ALVO

- PROFISSIONAIS MEDICINA E ENFERMAGEM VETERINÁRIA
- ESTUDANTES DE MEDICINA VETERINÁRIA
- ESTUDANTES DE ENFERMAGEM VETERINÁRIA

INSCRIÇÕES EM

inscricoes.cespu.pt

FARM4FUTURE
PRR Plano de Recuperação e Resiliência
REPÚBLICA PORTUGUESA
Financiado pela União Europeia NextGenerationEU
AENOR

Submit your work to:

OPEN ACCESS

Scientific Letters

ISSN 2795-5117 (online)

Scientific Letters is an **international peer-reviewed, fully open access journal**, free of charges, providing a forum for original research and critical contributions from **all areas of biology and medicine**, in the form of **original and review articles**.

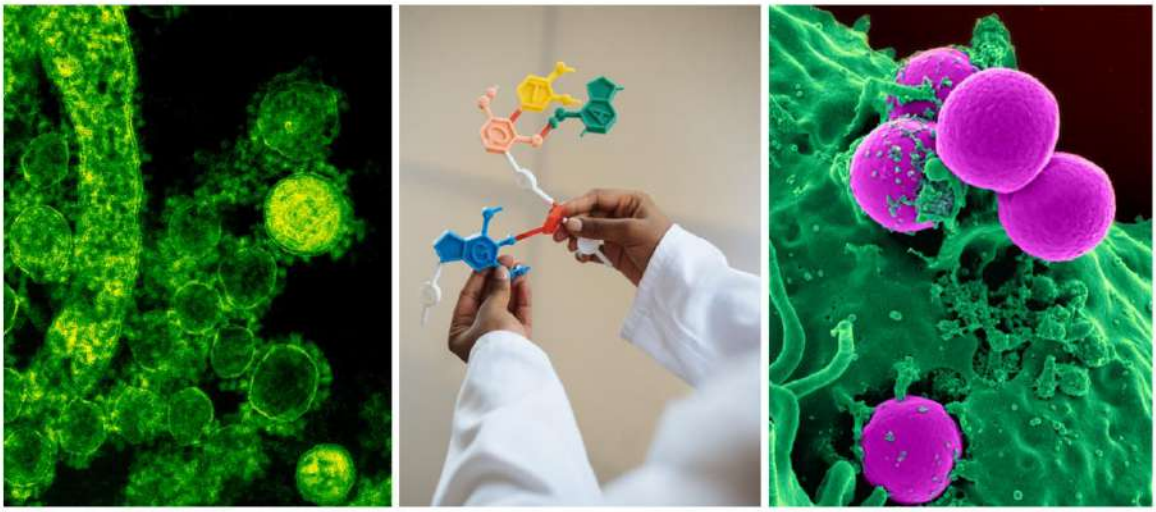

Scientific Letters (Sci Lett)
ISSN 2795-5117 (online)

- Fully open access, totally free of charges
- Rigorous peer-review process
- Effective Editorial Board
- DOI
- English editing (after acceptance)

The scientific journal of **CESPU University**

Editorial Team

Editor-in-chief: Hassan Bousbaa (PT) | **Section Editors:** Saman Warnakulasuriya (UK), Bruno Sarmento (PT), Maria Elizabeth Tiritan (PT), Ricardo Jorge Dinis-Oliveira (PT) Júlio C.M. Souza (PT), Quezia Bezerra Cass (BR), Bruno Henriques (BR), Vitor Bolanos-García (UK), Nuno Vieira Brito (PT), Arthur R.G. Cortes (MT), Célia F. Rodrigues (PT) | **Editorial Board:** Madalena Pinto (PT), José das Neves (PT), Odília Queirós (PT), Sara Ricardo (PT), Paolo De Marco (PT), Cláudia Ribeiro (PT), José Carlos Andrade (PT), Teresa Pinho (PT), Honorina Cidade (PT), Luís Monteiro (PT), Emília Sousa (PT) | **Copy Editor:** Joana Barbosa (PT) | **Production Editor:** Virginia Gonçalves (PT) | **Administrative Editor:** Rui Azevedo (PT)

CESPU University Publishing

CESPU UNIVERSITY

Authors of abstracts published in the present Book of Abstracts are cordially invited to submit their full manuscripts to *Scientific Letters* for publication. Please note that these manuscripts will undergo peer-review according to the review policy of the journal.

CONTENTS

CONTENTS 5
COMMITEES 7
VENUE 8
EDITORIAL 10
SCIENTIFIC PROGRAM 13
VETERINARY MEDICINE 13
VETERINARY NURSING 14
POSTER COMMUNICATIONS 16
VETERINARY MEDICINE 16
PC01 Retinal thickness assessment after secretome administration 16
PC02 Enhancing corneal regeneration with porcine *ex vivo* model 16
PC03 Insects: a healthy and sustainable alternative protein source in dog food? 17
PC04 Electrochemotherapy for recurrent cutaneous hemangiosarcoma in a dog: a case report 17
PC05 Factors influencing owners' decisions to consult a vet when pain is suspected in their dog 18
PC06 Owners' recognition of pain signs in dogs 18
PC07 Prevalence of *Dypilidium spp* in fleas collected from cats, dogs and hedgehogs in northern Portugal 19
PC08 Evaluation of fecal indicator bacteria in dry dog food after package opening: a public health concern 19
PC09 Molecular evidence of *Theileria equi* infection in horses from northern Portugal 20
PC10 Can the surgical sterilization process in veterinary medicine be sustainable? 21
PC11 Characterisation of Portuguese non-traditional companion animal caretakers 21
PC12 Assessment of microbial contamination level in veterinary medical centers in northern Portugal 22
PC13 Diagnostic contribution of the complete blood count in dogs and cats focus on degenerative and neoplastic conditions 22
PC14 Chitosan as a sustainable biopolymer from crustacean waste: opportunities of food safety 23
PC15 Electropermeabilization as the basis of electrochemotherapy in veterinary oncology 24
PC16 Clinical applications and the diagnostic and prognostic value of the NT-proBNP biomarker in myxomatous mitral valve disease in dogs: a review of current evidence 24
PC17 Geriatric polypharmacy: a 4-step algorithm to break the prescription cascade 25
PC18 Corneal transplantation as a therapeutic approach for corneal staphyloma in a dog 26
PC19 Hypertonic therapy for corneal oedema secondary to endothelial dystrophy in a dog 26
PC20 Fluorescence guided neurosurgery for intracranial neoplasm in veterinary practice 27
PC21 Exploring Staphylococcus species by MALDI-TOF-Mass spectrometry method in companion animals with infectious dermatitis 27
PC22 Q fever in Portugal: epidemiological analysis 2019-2023 in the European context and a One Health perspective 28
PC23 Case Report: osteomyelitis in a 6-month-old female rabbit, a relatively rare diagnosis with few reports in this specie, requiring lengthy tretament 29

PC24 Live animal markets: a pandemic waiting to happen – preliminary results....29
PC25 Risks associated with raw milk consumption: bacterial contamination....30
VETERINARY NURSING....31
PC26 Portuguese stray cats as potential reservoirs of *Giardia* and *Cryptosporidium*....31
PC27 Detection of *Anaplasma spp.* in free-roaming cats....31
PC28 Molecular detection of *Rickettsia spp.* in ticks collected from dogs in manaus, Barzil....32
PC29 Diagnostic and therapeutic approaches in canine stifle osteoarthritis: a literature review....32
PC30 The importance of aseptic technique in veterinary nursing during subcutaneous injections: a case of post injection subcutaneous abscess....33
PC31 Tick-borne *Ehrlichia spp.* in dogs from Manaus Brazil: a molecular surveillance study....33
PC32 Intervertebral disc disease in a French Bulldog: the role of postoperative rehabilitation....34
PC33 Zoonotic hazards in public spaces: detection of canine gastrointestinal parasites in Arcos de Valdevez....34
PC34 Environmental contamination with zoonotic parasites from dogs' faeces in public spaces in Ponte de Lima, Portugal....35
PC35 Gastrointestinal parasitic biodiversity of small ruminants in the north of Portugal....35
PC36 Biodiversity of gastrointestinal parasites in cattle of native breeds from northern Portugal....36
PC37 Gastrointestinal parasites wild ungulates from the north of Portugal....36
PC38 Coprological approaches for gastrointestinal parasites in wild birds admitted to a wildlife rehabilitation center....36
PC39 Prevalence of *Oxyuris spp.* in captive reptile species....37
PC40 Comparative prevalence of Anisakis spp. in selected commercial fish and cephalopods....38
PC41 Molecular surveillance of *Rickettsia spp.* in stray cats from Viana do Castelo....38
SPONSORS....41
ORGANIZED BY....41
SUPPORTED BY....41

COMMITEES

PRESIDENT OF THE ORGANIZING COMMITTEE

Gonçalo Petrucci, CESPU

ORGANIZING COMMITTEE

Veterinary Medicine

Nuno Brito, CESPU
Sónia Sá, CESPU
Mariana Lei, CESPU
Maria João Simões, CESPU
Leonor Delgado, CESPU
Hugo Gregório, CESPU
André Queirós, CESPU
Helena Real, CESPU

Veterinary Nursing

Rui Alvites, CESPU
Nuno Lima, CESPU
Stéphanie Buraco, CESPU
Sara Cuco, CESPU
Ana Marques, CESPU

SCIENTIFIC COMMITTEE

Veterinary Medicine

Gonçalo Petrucci, CESPU
Nuno Brito, CESPU
Ana Colette Maurício, ICBAS
Felisbina Queiroga, UTAD
Hugo Vilhena, ICBAS
Patrícia Sousa, ICBAS
Luís Maltez, UTAD
Bruno Colaço, UTAD
Teresa Villa de Brito, FMV

Veterinary Nursing

Rui Alvites, CESPU
Nuno Lima, CESPU
Ana Oliveira, IPLUSO
Gustavo Paixão, IPVC
Ana Lúcia Garcia, HV VetOeiras
Gonçalo Babau, ESSEM
Marta Braguez, ESAV-IPV
Pedro Bravo, ESAC
Fernando Esteves, ESAV-IPV

CONGRESS SECRETARIAT

Carla Guerreiro, CESPU
Marisa Freire, CESPU

Congress organized under the scientific coordination of IUCS-CESPU and IPSN-CESPU

VENUE

Centro Cultural de Paredes



Congress Venue: Centro de Congressos de Paredes

Address: Av. Dos Bombeiros Voluntários, 4580-053 Paredes

Phone: +351 255 006 460

EDITORIAL

EDITORIAL

The Knowledge Nexus: Research-Driven Higher Education and the Golden Age of Veterinary Geriatrics

Nuno Vieira e Brito[1,2,3], Rui Damazio Alvites[1,4,5] and Gonçalo Petrucci [1,6,7,8]

[1] University Institute of Health Sciences (IUCS), Polytechnic and University Higher Education Cooperative (CESPU), Avenida Central de Gandra, Gandra 1317, 4585-116, Portugal
[2] UCIBIO - Applied Molecular Biosciences Unit, Toxicologic Pathology Research Laboratory, University Institute of Health Sciences (1H-TOXRUN, IUCS-CESPU), 4585-116 Gandra, Portugal.
[3] CISAS, Escola Superior Agrária, Instituto Politécnico de Viana do Castelo, Rua Escola Industrial e Comercial de Nun´Álvares, 4900-347 Viana do Castelo, Portugal
[4] Associated Laboratory for Green Chemistry (REQUIMTELAQV), Institute of Sciences, Technologies and Agroenvironment of the University of Porto (ICETA), Rua D. Manuel II, Apartado 55142, Porto 4051-401, Portugal
[5] Department of Veterinary Clinics, Abel Salazar Institute of Biomedical Sciences (ICBAS), University of Porto (UP), Rua de Jorge Viterbo Ferreira, nº 228, Porto 4050-313, Portugal
[6] Onevetgroup Hospital Veterinário do Porto (HVP), Porto, Portugal
[7] Animal and Veterinary Research Centre (CECAV), University of Trás-os-Montes and Alto Douro, Vila Real, Portugal
[8] UNIPRO – Oral Pathology and Rehabilitation Research Unit, University Institute of Health Sciences (IUCS), CESPU, 4585-116 Gandra, Portugal

The modern institution of higher education stands on a foundation built by a dual imperative: the creation of knowledge through rigorous investigation and the dissemination of that knowledge through transformative teaching. Far from being separate, parallel endeavours, research and pedagogy are intrinsically linked.

Universities and other higher education organisations are not only places where students acquire technical skills and professional qualifications; they are also environments in which knowledge is created, questioned, tested, shared, and transformed. To truly understand the role of academia, it is worth recognising that universities are not mere repositories of information; they are dynamic ecosystems where knowledge is actively contested, refined, and reborn.

Higher education does not exist simply to pass down static traditions or historical facts; its true power lies in its capacity to push the boundaries of what is known and immediately translate those discoveries into the classroom and the wider world. The pedagogical framework of higher education relies on the concept that teaching becomes sterile the moment it detaches from active inquiry. When an institution isolates its teaching from research, it risks disseminating obsolete dogmas and preparing students for a world that no longer exists.

Research-driven academia establishes a critical feedback loop. Faculty members who actively engage in scientific investigation bring the raw, unfiltered reality of discovery into the lecture hall. They introduce students to the fluid nature of science, where hypotheses are tested, methodologies are questioned, and conclusions are constantly updated in light of new evidence. In veterinary sciences, this is visible whenever a long-held clinical protocol is revised considering new longitudinal data. Such an environment shifts the educational paradigm from rote learning (what to think) to epistemological literacy (how to evaluate evidence).

The quality and relevance of higher education depend greatly on the ability to transmit knowledge that is grounded in scientific investigation, critical thinking, and continuous innovation. When higher education institutions prioritize research-driven teaching, they fulfil their most vital societal mission. They transform students from passive consumers of information into critical thinkers, problem solvers, and future leaders capable of navigating complex, ever-evolving landscapes. This dynamic is visible across all academic disciplines, but it finds a particularly urgent and profound expression in the health sciences, and specifically, in the rapidly evolving field of veterinary sciences, where research findings translate almost immediately into changed clinical practice.

At the same time, higher education acts as the primary filter and translator of raw data into structured, ethical knowledge. Through peer review, academic debate, and rigorous methodological standards, universities ensure that society relies on validated science rather than fleeting trends or commercial interests. In an era saturated with fragmented information, the university remains the ultimate guarantor of intellectual integrity.

Furthermore, research-based knowledge transfer strengthens the connection between higher education institutions and society. Universities have a responsibility to contribute to the well-being of communities by producing knowledge that addresses social needs. Through research, academic institutions can support public policies, improve health and welfare, promote sustainability, and contribute to economic and technological development. Teaching becomes especially meaningful when students understand that their learning can have a positive impact beyond the classroom.

Another essential aspect of knowledge transmission is communication. Scientific knowledge has little value if it remains inaccessible to those who may benefit from it. Higher education institutions must therefore promote clear, rigorous, and inclusive communication between researchers, students, professionals, and the wider public. This includes the ability to translate complex scientific findings into practical recommendations and accessible language. In many areas, especially those related to health and animal welfare, effective communication can influence decisions that have significant

consequences for individuals, families, communities, and animals.

In the realm of veterinary sciences, the integration of research and teaching is uniquely complex. Veterinary scientists must master cross-species variations, public health intersections (One Health), and the delicate balance between emotional animal welfare and economic realities. This complexity is shared across the veterinary team, where nurses and clinicians alike must translate research into daily patient care. For decades, veterinary research focused heavily on herd health, infectious disease control, and acute surgical interventions. Higher education adapted accordingly, producing graduates exceptionally skilled at managing acute crises and production animal medicine.

However, science does not stand still. As research in nutrition, immunology, and pharmacology advanced within academic institutions, the baseline of veterinary care shifted dramatically. Animals began living significantly longer lives. This demographic shift in the animal population, driven by the very research generated within university walls, has created a brand-new mandate for veterinary education: There is an urgent need to understand, teach, and specialize in the aging animal. In just over a decade, the average lifespan of dogs has increased by approximately 12% and that of cats by 15%, with senior animals now representing nearly one third of the veterinary caseload (1-3). This is a direct consequence of scientific progress that now demands a new generation of veterinary professionals, both veterinarians and veterinary nurses trained in geriatric care

This brings us to the core focus of our current scientific discourse: the profound and growing relevance of geriatrics in modern veterinary medicine. As the central theme of this congress highlights, geriatric care is no longer a niche sub-specialty or an afterthought in general practice. It has become one of the most significant, daily realities faced by veterinary professionals worldwide.

Thanks to decades of research-driven breakthroughs in preventive care, vaccines, and advanced diagnostics, companion animals (as well as equine and livestock populations in specific contexts) are reaching ages that were virtually unseen half a century ago. Today, it is entirely common to treat twenty-year-old cats and fifteen-year-old large-breed dogs. With this longevity come new clinical realities, from chronic kidney disease and osteoarthritis to cognitive decline, that were far less prevalent a generation ago. However, longevity brings complexity. Aging is not merely the passage of time; it is a progressive, multi-systemic decline that requires a fundamentally different medical approach.

Geriatric veterinary care requires masterful communication regarding palliative care, pain assessment, and ultimately, end-of-life decisions. Higher education must treat these communication skills as core clinical competencies, backed by psychological and ethical research, ensuring that veterinary teams can guide families through the twilight years of their pets' lives with compassion, dignity, and scientific precision.

We investigate to discover new truths, and we teach to empower others with those truths. The rise of geriatrics in veterinary medicine is a shining testament to this cycle's success. It was academic research that allowed our animals to live long enough to require a dedicated field of geriatric medicine. Now, it is the responsibility of our universities and scientific congresses to gather, debate, and disseminate the specialized knowledge required to care for these senior patients. The 1st International Congress of Veterinary Sciences reflects exactly this responsibility. By anchoring our educational models in continuous scientific investigation, we ensure that the veterinary professions remain fully equipped to honor the human-animal bond at every stage of life.

References:

1. Montoya, M., Morrison, J. A., Arrignon, F., Spofford, N., Charles, H., Hours, M.-A., & Biourge, V. (2023). Life expectancy tables for dogs and cats derived from clinical data. Frontiers in Veterinary Science, 10, Article 1082102. https://doi.org/10.3389/fvets.2023.1082102
2. IDEXX Laboratories. (2024, October 4). 6 ways preventive care can help extend pets' lifespans. The Vetiverse. https://www.thevetiverse.com/en/latest/6-ways-preventive-care-can-help-extend-pets-lifespans/
3. Dhaliwal, R. S., Boynton, E., Carrera-Justiz, S., Cruise, N., Gardner, M., & Salisbury, S. (2023). 2023 AAHA senior care guidelines for dogs and cats. Journal of the American Animal Hospital Association, 59(1), 1–21. https://doi.org/10.5326/JAAHA-MS-7343

SCIENTIFIC PROGRAM

SCIENTIFIC PROGRAM

VETERINARY MEDICINE



VETERINARY NURSING



POSTER COMMUNICATIONS

POSTER COMMUNICATIONS

VETERINARY MEDICINE

PC01 Retinal thickness assessment after secretome administration

De Sousa Moreira A. [1,2*], **Lopes B.** [1,2], **Sousa A. C.** [1,2,3,4,5], **Sousa P.** [1,2], **Silva B.** [6,7], **Delgado E.** [6,7], **Amorim I.** [1,8], **Alvites R.** [1,2,3,9] **and Maurício A. C.** [1,2,3]

[1] LAQV, REQUIMTE, Instituto de Ciências, Tecnologias e Agroambiente (ICETA) da Universidade do Porto (UP), Porto, Portugal;
[2] Departamento de Clínicas Veterinárias, Instituto de Ciências Biomédicas de Abel Salazar (ICBAS - UP), Porto, Portugal;
[3] Associate Laboratory for Animal and Veterinary Sciences (AL4AnimalS), Faculdade de Medicina Veterinária (FMV), Universidade de Lisboa (UL), Lisboa, Portugal;
[4] RISE-Health, School of Medicine and Biomedical Sciences, Fernando Pessoa University, Fernando Pessoa Teaching and Culture Foundation, Gondomar, Portugal;
[5] Biomedical and Health Sciences (FP-BHS), Instituto de Investigação, Inovação e Desenvolvimento Fernando Pessoa (FP-I3ID), Fundação Ensino e Cultura Fernando Pessoa, Porto, Portugal;
[6] Centro de Investigação Interdisciplinar em Sanidade Animal (CIISA), FMV-UL, Lisboa, Portugal;
[7] HEV – Hospital Escolar Veterinário, FMV-UL, Lisboa, Portugal;
[8] i3S – Instituto de Investigação e Inovação da UP, Porto, Portugal;
[9] Cooperativa de Ensino Superior Politécnico e Universitário (CESPU), Gandra PRD, Portugal.

*Correspondent author: alicia.moreira.1998@gmail.com

ABSTRACT

Introduction and Aim: Glaucoma is a condition responsible for progressive and irreversible blindness in both humans and dogs. Current treatments fail to halt the progression of the disease, highlighting the need for novel therapeutic strategies. Mesenchymal stem cell (MSC) secretome has shown therapeutic promise in retinal disorders, including glaucoma. Before moving to disease models, it is crucial to establish the safety and tolerability of different administration routes for the MSC-derived secretome in healthy eyes. This study aimed to evaluate retinal structural integrity following subconjunctival (SbC) or intravitreal (ITV) administration of human umbilical cord MSCs derived-secretome in healthy rats. **Materials and Methods:** Twenty-four Wistar Hannover albino rats were divided into four groups (n = 6/group) according to administration route (SbC or ITV) and timepoint (euthanasia at day 5 or 28 post-treatment). The MSC-derived secretome was injected into the right eye of each animal. After the considered timepoints, ocular globes were collected, paraffin-embedded, sectioned, stained with hematoxylin–eosin, and examined by light microscopy. Retinal thickness was quantified using QuPath, focusing on the total retina (TOTAL), the inner nuclear layer (INL), and the outer nuclear layer (ONL). Measurements were compared between treated (OD) and contralateral control (OS) eyes, as well as across experimental groups, and statistical analyses were performed to assess group differences. **Results**: No significant differences in retinal thickness were found between treated and control eyes within any group, confirming the contralateral eye as a reliable internal control. The INL remained stable across groups, with only a slight but significant reduction in the ITV 28-day group compared with SbC. More pronounced changes were observed in the ONL, which showed significant thinning in ITV-treated eyes, particularly 28 days post-treatment. Total retinal thickness followed the same pattern, with reduced values in the ITV 28-day group compared to SbC at both timepoints. Conversely, SbC-treated eyes maintained consistent thickness across time. **Conclusions**: Histological analysis supports the safety of the SbC administration route, with no adverse retinal alterations detected. In contrast, the ITV route was associated with subtle thinning of the ONL over time, suggesting a higher risk of structural alterations, possibly related to local injection-induced effects or direct intraocular exposure. These findings support the SbC route as a safer and less invasive option for future preclinical studies involving stem cell-derived secretome.

Funding
This work was supported by FCT Grant 2023.00544.BD, AL4AnimalS 2023 Internal Project (LT3.9) and the 2024 ESVO Research Grant.

Conflict of Interest Declaration
The authors declare no conflicts of interest.

PC02 Enhancing corneal regeneration with porcine *ex vivo* model

Araújo A.[1,2*], **Alvites R.**[1,2,3,4], **Maurício A.**[1,2,3], **Delgado E.**[2,5]

[1] School of Medicine and Biomedical Sciences (ICBAS), University of Porto, Porto, Portugal
[2] Associate Laboratory for Animal and Veterinary Sciences (AL4AnimalS), Faculty of Veterinary Medicine, University of Lisbon, Lisbon, Portugal
[3] Associated Laboratory for Green Chemistry (REQUIMTE-LAQV), Institute of Science, Technology and Agro-environment of the University of Porto (ICETA), Porto, Portugal
[4] University Institute of Health Sciences (IUCS-CESPU), Gandra, Portugal
[5] Centre for Interdisciplinary Research in Animal Health (CIISA), Faculty of Veterinary Medicine, University of Lisbon, Lisbon, Portugal.

*Correspondent author: araujoana_1@hotmail.com

ABSTRACT

Introduction and Aim: Corneal diseases remain a major concern in veterinary ophthalmology [1], with severe ulcers representing a significant therapeutic challenge, highlighting the urgent need for innovative and effective therapies. [2]. The porcine cornea ex vivo model aims to mimic *in vivo* conditions and, due to its accessibility and the capacity to allow the isolation of multiple ocular cell populations, provides a robust alternative for investigating corneal wound healing mechanisms and assessing the efficacy of emerging therapeutic approaches, while complying with the principles of ethical research and reduction of live animal use [3]. This study evaluated the effects of fetal bovine serum (FBS) and dextran (DEX) supplementation on corneal regeneration using a porcine *ex vivo* model over 14 days culture period. **Materials and Methods:** Fresh porcine eyes (n=6) were collected post-mortem in a slaughterhouse authorized by the national authority, the Directorate-General for Food and Veterinary Medicine (DGAV) and subjected to a standardized 4 mm central corneal defect. Corneas were cultured in Dulbecco's Modified Eagle Medium (DMEM) under three different conditions: Group A (10% FBS), Group B (6% DEX), and Group C (10% FBS + 6% DEX). The re-epithelialization rate

was determined by measuring the ulcer area through stereomicroscopy and ImageJ software analysis. **Results:** After 14 days, Group A achieved complete epithelial regeneration, Group B demonstrated significant wound reduction (1,88 mm² remaining defect), and Group C exhibited minimal healing (11,55 mm² remaining defect). The highest re-epithelialization rates occurred within the first 48 hours, particularly in Groups A and B, (0,041 mm²/h and 0,035 mm²/h, respectively) compared to Group C (0,006 mm²/h). Healing progression slowed after day 8, although Group A maintained the highest regeneration rate. **Conclusions:** These findings suggest that supplementation with FBS and DEX supports corneal healing, with FBS supplementation alone (Group A) providing the most effective regenerative response under the tested conditions. Despite the exploratory design and small sample size, the *ex vivo* model demonstrated reliability and reproducibility for studying corneal repair mechanisms. Further studies with larger sample size and optimized methodologies are warranted to validate these results and explore the potential of this *ex vivo* model for testing innovative pro-regenerative therapies in corneal disease, including biomaterials, cell-free therapies, and cell-based approaches, contributing to both veterinary and comparative ophthalmology.

Funding
This work is partially supported by REQUIMTE-LAQV; UIDB/00211/2020 and AL4AnimalS LA/P/0059/2020. The authors acknowledge FCT for funding the project 2022.04501.PTDC. Ana Araújo acknowledges the Seara S.A., ICBAS-UP, CIISA-FMV and REQUIMTE-LAQV /ICETA for the funding and availability of all technical, structural, and human resources necessary for the development of this work.

Conflict of Interest Declaration
The authors declare no conflicts of interest.

PC03 Insects: a healthy and sustainable alternative protein source in dog food?

Paulo A.[1*], Malherbe S.[1], Afonso P.[1,2], Real H.[1,2]

[1] IUCS - University Institute of Health Sciences, CESPU, Paredes, Portugal
[2] 1H-TOXRUN – One Health Toxicology Research Unit, Avenida Central de Gandra, n.º 1317, 4585-116 Gandra, Portugal.

*Correspondent author: a31934@alunos.cespu.pt

ABSTRACT

Introduction and Aim: The increase in the canine population in Portugal requires new food solutions, as traditional pet foods involve high environmental costs and risks of obesity due to excess nutrients. There is, therefore, a need to seek sustainable and healthy alternatives. This study aims to analyse the composition of dog foods that contain insects as an alternative protein source. **Materials and Methods:** Five online pet food sales websites were consulted, and information was collected from the labels of dog foods containing insects in their composition. The following elements were collected: list of ingredients, nutritional composition, food origin, sustainability labels, and price. **Results:** Thirty-two foods were analyzed. The black soldier fly larva (*Hermetia illucens*) was the only insect identified, used alone (20-30%) or mixed with other flours such as chicken or fish (10-14%). Nutritionally, the feeds meet the requirements of the European Pet Food Industry Federation (FEDIAF) and the American Association of Food Control Officers (AAFCO). Labels are rare on the packaging analyzed. The few exceptions found included designations such as “Eco-friendly protein,” “green pet food,” “sustainable,” “made in Germany,” and mentions of recyclable packaging. Similarly, for the place of origin, many feeds do not indicate it, implying the need to search directly. For feeds that indicate their origin, Germany is clearly the predominant country of origin. **Conclusions:** *Hermetia illucens*-based feeds represent a viable, hypoallergenic alternative that meets the nutritional needs of dogs with a considerably reduced ecological footprint, since the production of 1 kg of pure *Hermetia illucens* protein emits only 0.042 kg of CO2 equivalent (compared to 21.2 kg for chicken) and allows for the revaluation of local waste.

Funding
No applicable.

Conflict of Interest Declaration
No applicable.

PC04 Electrochemotherapy for recurrent cutaneous hemangiosarcoma in a dog: a case report

Salazar M.[1]*, Queiroga F.[1], Rodríguez-Pizà I.[2]

[1] University of Trás-Os-Montes e Alto Douro, Vila Real, Portugal
[2] Anicura Glòries Hospital Veterinari, Barcelona, Spain.

*Correspondent author: martafsalazar@gmail.com

ABSTRACT

Case Description: An 11-year-old intact male Pitbull was referred for evaluation of multiple recurrent cutaneous lesions located on the preputial region. The patient had relevant oncological history, including prior peritesticular mast cell tumour and grade II cutaneous hemangiosarcoma of the prepuce, both surgically excised. In addition, the dog had been previously diagnosed with leishmaniosis and was under chronic medical management. At presentation the patient was clinically stable and no signs were reported by the owners. The physical examination revealed multiple small nodular cutaneous lesions distributed on both sides of the prepuce, characterized by dark and haemorrhagic coloration, with adjacent erythema. Complementarily, further diagnostic exams were performed, such as complete blood count, serum biochemistry, abdominal ultrasonography and three-view thoracic radiography, all of which were unremarkable. Fine-needle aspiration cytology of the inguinal lymph nodes confirmed the absence of metastatic infiltration. Considering the clinical history, morphological characteristics, anatomical location and the absence of detectable metastatic disease, a presumptive diagnosis of recurrent cutaneous hemangiosarcoma was established. The patient was considered a suitable candidate for electrochemotherapy (ECT). The procedure was performed according to the Standard Operating Procedures under general anaesthesia. Bleomycin was administered, followed by the delivery of eight biphasic electric pulses using parallel-needle electrodes. The procedure was well tolerated, with no intraoperative complications, and post-procedural analgesia was prescribed. Three weeks after the first ECT session the

lesions had resolved, without adverse effects or systemic toxicity. **Discussion:** This case illustrates the clinical applicability of ECT as a minimally invasive local treatment for recurrent cutaneous hemangiosarcoma in dogs. The accessible anatomical location, absence of detectable metastatic disease and prior unsuccessful surgical approach supported the selection of ECT as a tissue-sparing therapeutic option. The favourable clinical response observed in this patient is consistent with reports describing effective local tumour control, good tolerability and reduced recurrence rates of ECT in cutaneous and subcutaneous neoplasms. These findings highlight the potential role of ECT as an alternative or complementary modality in cases where repeated surgical intervention may compromise anatomical function or quality of life.

Funding
Not applicable.

Conflict of Interest Declaration
The authors declare no conflicts of interest.

PC05 Factors influencing owners' decisions to consult a vet when pain is suspected in their dog

Panerai E.[1]*, Lopes J.[1], Afonso P.[1,2,3]

[1] Polytechnic and University Higher Education Cooperative (CESPU), University Institute of Health Sciences (IUCS), Gandra, Portugal.
[2] Associate Laboratory i4HB - Institute for Health and Bioeconomy, University Institute of Health Sciences - CESPU, 4585-116 Gandra, Portugal.
[3] UCIBIO - Applied Molecular Biosciences Unit, Translational Toxicology Research Laboratory, University Institute of Health Sciences (1H-TOXRUN, IUCS-CESPU), 4585-116 Gandra, Portugal.

*Correspondent author: a30472@alunos.cespu.pt

ABSTRACT

Introduction and Aim: In some cases, pain in dogs is underestimated by owners, thus delaying a visit to the vet and the animal's treatment. Sometimes, downplaying these signs can have serious consequences for the animal's health. This is why understanding the factors that influence owners' decisions to consult a vet when pain is suspected is essential to improve access to veterinary care and treatment. The aim of this study is to identify the obstacles that may delay or prevent owners from seeking veterinary advice when they suspect their dog is in pain. **Materials and Methods:** To this end, a cross-sectional questionnaire study was conducted among dog owners in the Auvergne-Rhône-Alpes region (France). This questionnaire aimed to analyse owners' behaviour in cases of suspected pain, whether they consult a vet immediately or, if not, the reasons for not doing so (cost, lack of knowledge, lack of time, etc.). The questionnaire was made available online, primarily in Facebook groups gathering dog owners in the Auvergne-Rhône-Alpes region. It was also shared on Instagram and disseminated by volunteer participants. All data were collected anonymously. The collected data were subjected to descriptive analysis to identify the main barriers to seeking veterinary care. **Results:** Preliminary results indicate that the majority of owners do consult a veterinarian when they suspect signs of pain. However, when they don't consult, the main reasons cited were that the dog seemed fine, uncertainty about the clinical signs and a preference to wait. For those owners who reported not consulting, the primary barriers identified were uncertainty about the severity of the clinical signs and the cost of the veterinary consultation. **Conclusions:** In conclusion, this study will provide a better understanding of the factors that may delay or prevent veterinary consultation in cases of suspected pain in dogs. Identifying these obstacles could improve veterinary care by fostering owner-veterinarian communication and developing awareness strategies to promote early intervention.

Funding
Not applicable.

Conflict of Interest Declaration
The authors declare no conflicts of interest.

PC06 Owners' recognition of pain signs in dogs

Panerai E.[1]*, Lopes J.[1], Afonso P.[1,2,3]

[1] Polytechnic and University Higher Education Cooperative (CESPU), University Institute of Health Sciences (IUCS), Gandra, Portugal.
[2] Associate Laboratory i4HB - Institute for Health and Bioeconomy, University Institute of Health Sciences - CESPU, 4585-116 Gandra, Portugal.
[3] UCIBIO - Applied Molecular Biosciences Unit, Translational Toxicology Research Laboratory, University Institute of Health Sciences (1H-TOXRUN, IUCS-CESPU), 4585-116 Gandra, Portugal.

*Correspondent author: a30472@alunos.cespu.pt

ABSTRACT

Introduction and Aim: In veterinary clinics, it is common to see dogs presenting signs of pain for several days or weeks. Sometimes, the wait for a consultation can have irreversible consequences for an animal's care. The owner's ability to recognize signs of pain in their pet is essential for improving animal welfare and promoting early intervention. The objective of this study is to assess dog owners' ability to recognize the various clinical and behavioural signs that may be associated with pain in their pets. To this end, a cross-sectional questionnaire-based study was conducted among dog owners in the Auvergne-Rhône-Alpes region of France. This questionnaire included questions on various clinical and behavioural signs of pain, allowing owners to indicate whether they consider these behaviours to be signs of pain. **Materials and Methods:** The questionnaire was made available online, primarily in Facebook groups gathering dog owners in the Auvergne-Rhône-Alpes region. It was also shared on Instagram and disseminated by volunteer participants. All data were collected anonymously. The collected data were analysed descriptively to identify the most frequently reported signs of pain by owners. **Results:** Preliminary results show that most participants tend to recognise physical signs of pain, such as moaning/vocalisations, refusal to move and licking/biting the same area. Behavioural signs are generally less well recognised although overreactions, sudden aggressiveness and changes in appetite were noted by several owners. **Conclusions:** In conclusion, this study will provide a better understanding of owners' perception of canine pain and identify any gaps in the recognition of certain physical or behavioural clinical signs. This study could contribute to improving owners' knowledge, thereby improving animal welfare and enabling the early

management of certain pathologies that may manifest as signs of pain.

Funding
Not applicable.

Conflict of Interest Declaration
The authors declare no conflicts of interest.

PC07 Prevalence of *Dypilidium spp* in fleas collected from cats, dogs and hedgehogs in northern Portugal

Moreira D.[1]*, Espíndula C.[1], Barradas P.[2]

[1] Animal and Veterinary Department, University Institute of Health Sciences, CESPU, CRL, 17 4585 116 Gandra, Portugal
[2] UCIBIO, Applied Molecular Biosciences Unit, University Institute of Health Sciences, IUCS-CESPU, Rua Central de Gandra, 1317, 4585-116 Gandra PRD, Portugal
[3] CECAV - Veterinary and Animal Research Center, University of Trás-os-Montes e Alto Douro, Quinta de Prados, Vila Real 5000-801, Portugal.

*Correspondent author: a30326@alunos.cespu.pt

ABSTRACT

Introduction and Aim: Fleas are globally distributed hematophagous ectoparasites with a well-established role in the transmission of vector-borne pathogens. Among these, Dipylidium caninum is a zoonotic cestode of significant one health importance, affecting dogs and cats with rare human infections, particularly in children. The transmission occurs through the ingestion of infected fleas with cysticercoid larvae, highlighting the epidemiological relevance of flea populations. This study aimed to determine the prevalence of Dipylidium spp. In fleas collected from companion animals and hedgehogs in northern Portugal, representing the first molecular study of this parasite in fleas from this region. **Materials and Methods:** A total of 135 fleas were collected from cats, dogs and hedgehogs across two districts in northern Portugal (Porto and Viana do Castelo). Specimens were obtained using fine-toothed combing (domestic animals) and manual collection (hedgehogs) and preserved in 70% ethanol. Morphological identification was performed using stereoscopic and light microscopy. Genomic DNA was extracted from individual fleas using NZY Tissue gDNA Isolation Kit, following the manufacturer's instructions. Detection of D. caninum was carried out using conventional PCR targeting a fragment of the 28S rRNA gene. Flea species identification was molecularly confirmed through amplification of the cytochrome oxidase subunit II (COX-2) gene in a subset of samples. Positive amplicons were sequenced using the Sanger method and analysed through comparison with sequences available in the GenBank database. **Results:** Fleas were identified as *Ctenocephalides felis*, *Ctenocephalides canis* and *Archaeopsylla erinacei*. Of the 135 specimens analysed D. caninum DNA was detected in 2 (1,5%) fleas, both belonging to *C. felis*, confirming the presence of infected fleas in the study area despite the low prevalence observed. No evidence of infection was found in *C. canis* or *A. erinacei*. These findings reinforce the role of *C. felis* as the primary intermediate host in this geographical setting. **Conclusions:** Despite the low prevalence observed, the detection of *D. caninum* in *C. felis* supports its continued circulation and zoonotic potential in northern Portugal. The absence of infection in other flea species suggests limited epidemiological role, although further studies are needed. These findings emphasise the importance of integrated parasite control strategies, including consistent ectoparasite management and routine anthelmintic protocols. Veterinary professionals are central to implementing preventive measures and raising owner awareness of zoonotic risks.

Funding
Not applicable.

Conflict of Interest Declaration
The authors declare no conflicts of interest.

PC08 Evaluation of fecal indicator bacteria in dry dog food after package opening: a public health concern

Miranda C.[1,2,3,4,*], Sousa M.[1], Cardoso A.[1], Simões M.J.[1,5,6], Brito N.[1,2,3,7]

[1] University Institute of Health Sciences, Cooperativa de Ensino Superior Politécnico e Universitário (IUCS-CESPU), Avenida Central de Gandra 1317, 4585-116 Paredes, Portugal
[2] UCIBIO-—Applied Molecular Biosciences Unit, University Institute of Health Sciences (1H-TOXRUN, IUCS-CESPU), Avenida Central de Gandra 1317, 4585-116 Paredes, Portugal
[3] Associate Laboratory i4HB - Institute for Health and Bioeconomy, University Institute of Health Sciences, CESPU, 4585-116 Gandra, Portugal
[4] LAQV-REQUIMTE—Associated Laboratory for Green Chemistry, University NOVA of Lisbon, 1099-085 Caparica, Portugal
[5] LAQV-REQUIMTE—Associated Laboratory for Green Chemistry, Institute of Science, Technology and Agro-Environment of the University of Porto (ICETA), Porto, Portugal
[6] AL4AnimalS —Laboratory for Animal and Veterinary Sciences, Faculty of Veterinary Medicine, University of Lisbon, Lisbon, Portugal
[7] CISAS—Center for Research and Development in Agrifood Systems and Sustainability, Polytechnic Institute of Viana do Castelo (IPVC) 4900-347 Viana do Castelo, Portugal.

*Correspondent author: carla.miranda@iucs.cespu.pt

ABSTRACT

Introduction and Aim: The growing concern for public health, animal health and welfare has driven research on microbiological contamination in pet food. Although feed processing, packaging conditions, and storage parameters, such as temperature and humidity are subject to strict regulatory oversight and have been extensively studied to mitigate the presence of pathogenic microorganisms, studies evaluating contamination after package opening and potential external sources of contamination remain limited. Dry pet foods, particularly those sold in bulk, repackaged at retail sites or improperly stored in domestic environments, have increasingly been recognized as potential vehicles for pathogenic microorganisms, including multidrug-resistant bacteria. Staphylococcus aureus, Escherichia coli, and Enterococcus spp. have frequently been isolated from these products, indicating possible fecal contamination, poor handling hygiene, or environmental exposure. This study aims to evaluate the microbiological quality, including fecal bacterial indicators, of post-opening dry dog food, both packaged and sold in bulk, marketed in Portugal. **Materials and Methods:** A total of 20 dry food samples representing 18 different brands were randomly collected from 15 domestic environments and 5 retail markets selling pet food in bulk, in Portugal. For each sample, two subsamples were taken: one at day 0 (package opening) and

another at day 5 (after exposure), totaling 40 subsamples. Each subsample was pre-enriched in brain heart infusion broth and subsequently plated onto selective media, such as MacConkey and Slanetz-Bartley (with/without 6µg/ml vancomycin), for the isolation of Escherichia coli and Enterococcus spp., respectively. Typical colonies (one to two per plate) were identified using standard biochemical tests. **Results:** Enterococcus spp. were detected in 12/20 (60%) samples, including 8 positives in both subsamples and 4 in one subsample. Nine (75%) of the positive samples were collected in domestic environments and three in retail markets selling pet food in bulk. In two bulk samples, Enterococcus spp. were detected both at package opening and after 5 days. Overall, 43 Enterococcus isolates were recovered from 20/40 (50%) subsamples. Among these, 17/43 (40%) isolates grew on Slanetz-Bartley agar with vancomycin-supplemented, indicating potential phenotypic resistance. Most isolates were obtained from canine feeds collected in domestic environments (31/43, 72%), including 12 isolates that grew in vancomycin-supplemented media, while remaining isolates were from bulk retail samples (12/43, 28%), of which 5 grew in vancomycin-supplemented media. No *Escherichia coli* was detected. **Conclusions:** Detection of *Enterococcus spp*. in a substantial proportion of post-opening dry dog food samples, including isolates showing growth in vancomycin-supplemented media, suggests microbial contamination may occur or persist after package opening in both domestic environments and bulk retail settings. The higher number of isolates recovered from feeds stored in domestic environments indicates that household handling and storage conditions may contribute to microbial presence. Although *Escherichia coli* was not detected, the occurrence of Enterococcus spp., commonly used as fecal indicator bacteria, highlights the need for improved hygiene practices during storage and handling of pet food after opening. These findings support the importance of further investigations into post-opening contamination routes, and effective campaign of sensibilization concerning pet food handling and storage to reduce the potential public and animal health implications.

Funding
This work was funded by the 1H-TOXRUN of the University Institute of Health Sciences (IUCS-CESPU), and from FCT/MCTES for the national funds (UIDB/50006/2020 DOI 10.54499/UIDB/50006/2020, UIDP/50006/2020, UIDB/04378/2020 and LA/P/0140/2020).

Conflict of Interest Declaration
The authors declare no conflicts of interest.

PC09 Molecular evidence of *Theileria equi* infection in horses from northern Portugal

Campos M.[1] *, Dias J.[1], Maia M.[1], Queiroz M.[1], Sá J.[1], Leal Reis I. [1,2], Brito N.V. [1,3,4], Barradas P. [1,3,5]

[1] Instituto Universitário de Ciências da Saúde, Cooperativa de Ensino Superior Politécnico e Universitário (CESPU), CRL, 4585-116 Gandra, Portugal
[2] Instituto de Ciências Biomédicas de Abel Salazar (ICBAS), Universidade do Porto (UP), Rua de Jorge Viterbo Ferreira, nº 228, 4050-313 Porto, Portugal.
[3] UCIBIO, Applied Molecular Biosciences Unit, University Institute of Health Sciences, IUCS-CESPU, Rua Central de Gandra, 1317, 4585-116 Gandra PRD, Portugal
[4] CISAS, Escola Superior Agrária, Instituto Politécnico de Viana do Castelo, Rua Escola Industrial e Comercial de Nun´Álvares, 4900-347 Viana do Castelo, Portugal
[5] CECAV - Veterinary and Animal Research Center, University of Trás-os-Montes e Alto Douro, Quinta de Prados, Vila Real 5000-801, Portugal.

*Correspondent author: a31298@alunos.cespu.pt

ABSTRACT

Introduction and Aim: Equine piroplasmosis (EP) is a tick-borne protozoan disease caused by *Theileria equi* and *Babesia caballi*. These two intraerythrocytic parasites have a significant clinical and economic impact on the equestrian industry worldwide. Infected animals frequently become asymptomatic carriers, perpetuating the transmission cycle and complicating disease control. In Portugal, EP is considered endemic, with regional prevalence varying considerably. Despite its recognized importance, data on EP distribution in Northern Portugal remains limited, warranting targeted epidemiological investigation. This study aims to contribute to the determination of the prevalence of *Theileria equi* and *Babesia caballi* in Northern Portugal and to contribute to epidemiological data for the control of equine piroplasmosis. **Materials and Methods:** A cross-sectional study was performed in five districts of Northern Portugal (Porto, Braga, Viana do Castelo, Viseu, and Bragança), during which 133 blood samples were collected by jugular venipuncture into EDTA tubes. Epidemiological data, including age, sex, movement history, and clinical signs, were recorded for each animal. Total genomic DNA was extracted using the NZY Tissue gDNA Isolation Kit® according to the manufacturer's instructions. PCR amplification targeting the 18S rRNA gene was used for molecular detection, allowing the simultaneous identification of *Theileria equi* and *Babesia caballi*. All positive samples were confirmed by DNA sequence analysis. **Results:** Prevalence rates were calculated, and associations between risk factors, including inter-regional movement history and infection status were analysed. Out of the 133 equine blood samples analyzed, nine (6.77%) tested positive for *Theileria equi*, while no *Babesia caballi* infections were detected. Positive cases were identified in two of the five districts sampled. Porto presented the highest number of positive cases (11,94 %), followed by Viana do Castelo (6,25 %). No positive results were detected in the blood samples collected in Braga, Viseu, or Bragança. **Conclusions:** Despite a small sample, this study indicates the presence and regional variation of EP in Northern Portugal, with an overall prevalence of 6.77%. The exclusive detection of *T. equi* and the association between positive cases and movement history underscores the epidemiological relevance of asymptomatic carrier animals in disease perpetuation. Having in mind that the current available therapies mitigate selectively *B. caballi*, the persistence of such carriers and the limitations of current therapeutic options highlight the urgent need for improved diagnostic tools and integrated control measures. Enhanced epidemiological surveillance, including more frequent and routine blood screening in endemic areas, should be prioritized to improve early detection and control of equine piroplasmosis. Preventive measures targeting vectors such as tick management and control of ectoparasites remain important, however, the increasing limitations associated with ectoparasiticide and endoparasiticide use, particularly due to rising resistance, highlight the need to emphasize epidemiological monitoring as a central control strategy.

Funding
Not Applicable.

Conflict of Interest Declaration
The authors declare no conflicts of interest.

PC10 Can the surgical sterilization process in veterinary medicine be sustainable?

Cros E.[1], Tur E.[1], Le Gall M.[1], Ferrari P.[1*], Afonso P.[1,2], Real H.[1,2]

[1] IUCS - University Institute of Health Sciences, CESPU, Paredes, Portugal
[2] 1H-TOXRUN – One Health Toxicology Research Unit, Avenida Central de Gandra, n.º 1317, 4585-116 Gandra, Portugal.

*Correspondent author: a31599@alunos.cespu.pt

ABSTRACT

Introduction and Aim: In the context of global warming and growing concern for environmental health, veterinarians, as part of the 'One Health' approach, play a key role. Pets are now considered full members of our households in Europe. Growing concern for their welfare has led to increased veterinary care in Europe. In clinical practice, surgery has the largest carbon footprint. And of all operations, sterilisation is by far the most common in all veterinary facilities. The use of volatile anaesthesia, sterile surgical instruments, and the repeated use of autoclaves, instrument packaging, surgical lights, and waste production, as well as the use of large quantities of water, are all critical issues that need to be addressed for the good of the planet. The aim of this study was to assess the sustainability of surgical sterilization in veterinary medicine by analysing resource consumption patterns and identifying evidence-based strategies to reduce their environmental impact. **Materials and Methods:** From October to December 2025, a research was conducted on Pubmed, Dumas, Google Scholar, and other scientific platforms, using the search terms (waste OR sustaina* OR energ*) AND (veterinar* OR surgery), focusing on articles published between 2005 and 2025 with accessible full texts. Studies were selected based on relevance to veterinary surgical practices and environmental impact, while duplicates and insufficiently detailed articles were excluded. A total of 12 articles were included. Data were qualitatively analysed through thematic synthesis, focusing on four main domains: water consumption, energy use, waste production, and behavioral and educational factors related to professionals. Identified interventions were critically evaluated based on feasibility, reported impact and applicability to veterinary settings. **Results:** The analysis highlights that surgical sterilization is associated with substantial consumption of water, electricity and disposable materials, largely driven by hygiene protocols, equipment use and organizational practices. In addition, a lack of awareness and training among practitioners contributes to inefficient resource use. Multiple strategies were identified to limit this impact, including the use of alcohol-based hand disinfection, energy-efficient equipment, optimization of surgical scheduling, reduction of disposable materials and improved waste management and enhanced practitioner education. When combined, these measures have the potential to significantly reduce resource consumption without compromising clinical outcomes. Based on this synthesis, where various solutions used in clinicals and hospitals were identified, an infographic was developed as a knowledge translation tool to support the implementation of sustainable practices in clinical settings. **Conclusions:** These findings highlight the importance of mobilising the veterinary profession to help limit global warming and ensure a healthy planet for future generations. While surgical sterilization is inherently resource-intensive, it can be considered more sustainable if evidence-based strategies are systematically implemented. Further research is needed to quantify the environmental impact of these interventions and support their large-scale adoption.

Funding
Not Applicable.

Conflict of Interest Declaration
Not applicable.

PC11 Characterisation of Portuguese non-traditional companion animal caretakers

Cardoso-Freitas F.[1*], Martinez-Silvestre A.[2], Martins A.[1,3], Poeta P.[1,3,4,5]

[1] Veterinary and Animal Research Centre (CECAV), University of Trás-Os-Montes and Alto Douro (UTAD), 5000-801 Vila Real, Portugal
[2] Catalonian Reptiles and Amphibians Rescue Center (CRARC), 08783 Masquefa, Barcelona, Spain
[3] Associate Laboratory for Animal and Veterinary Sciences (AL4AnimalS), 5000-801 Vila Real, Portugal
[4] MicroART – Microbiology and Antibiotic Resistance Team, Department of Veterinary Sciences, University of Trás-Os-Montes and Alto Douro (UTAD), 5000-801 Vila Real, Portugal
[5] Associate Laboratory for Green Chemistry (LAQV-REQUIMTE), University NOVA of Lisboa, 1099-085 Lisboa, Portugal.

*Correspondent author: al53178@alunos.utad.pt

ABSTRACT

Introduction and Aim: The wide variety of animals excluding farm animals, dogs and cats that are kept as pets are defined as non-traditional companion animals, or more informally "exotics". The number of these pets has been increasing. Specifically in Portugal, there is an estimated a million of non-traditional companion animals, accounting for 18% of the total pet population. It is known that if an animal is maintained illegally, the caretaker is less likely to reach out to a veterinarian, negatively impacting the animal's welfare. The aim of this study was to characterise the caretakers of these animals, including the types of pets they had and their legal status. **Materials and Methods:** The wide variety of animals excluding farm animals, dogs and cats that are kept as pets are defined as non-traditional companion animals, or more informally "exotics". The number of these pets has been increasing. Specifically in Portugal, there is an estimated a million of non-traditional companion animals, accounting for 18% of the total pet population. It is known that if an animal is maintained illegally, the caretaker is less likely to reach out to a veterinarian, negatively impacting the animal's welfare. The aim of this study was to characterise the caretakers of these animals, including the types of pets they had and their legal status. **Results:** The caretakers were characterised demographically (gender, age, marriage status), which species they had previously kept, the goal for keeping them and what information they had on the species they had kept. **Conclusions:** The results described here help to describe caretakers of non-traditional companion animals. It's important to note that the majority of them did their investigation related

to the species prior to the acquisition of the animal. However, only just over half of the respondents knew what CITES was, and less than half had the necessary documentation to keep these animals legally. Mammals were the most common animal, and most of them were pets and had no reproductive interest.

Funding
This work was supported by the projects UI/00772 and LA/P/0059/2020 funded by Portuguese Foundation for Science and Technology (FCT).

Conflict of Interest Declaration
Not applicable.

PC12 Assessment of microbial contamination level in veterinary medical centers in northern Portugal

Miranda C.[1,2,3,4,†,*], Simões M.J.[1,5,6,†], Sousa M.[1], Cardoso A.[1], Brito NV[1,3,4,7]

[1] University Institute of Health Sciences, Cooperativa de Ensino Superior Politécnico e Universitário (IUCS-CESPU), Avenida Central de Gandra, Paredes, Portugal
[2] LAQV-REQUIMTE—Associated Laboratory for Green Chemistry, University NOVA of Lisbon, Caparica, Portugal
[3] UCIBIO-—Applied Molecular Biosciences Unit, University Institute of Health Sciences (1H-TOXRUN, IUCS-CESPU), Avenida Central de Gandra, Paredes, Portugal
[4] Associate Laboratory i4HB - Institute for Health and Bioeconomy, University Institute of Health Sciences, CESPU, Gandra, Portugal
[5] LAQV-REQUIMTE—Associated Laboratory for Green Chemistry, Institute of Science, Technology and Agro-Environment of the University of Porto (ICETA), Porto, Portugal
[6] AL4AnimalS —Laboratory for Animal and Veterinary Sciences, Faculty of Veterinary Medicine, University of Lisbon, Lisbon, Portugal
[7] CISAS—Center for Research and Development in Agrifood Systems and Sustainability, Polytechnic Institute of Viana do Castelo (IPVC), Viana do Castelo, Portugal.

† These authors contributed equally to this work.

*Correspondent author: carla.miranda@iucs.cespu.pt

ABSTRACT

Introduction and Aim: Veterinary care centers (VCCs), particularly clinical and surgical environments, are critical areas where microbial contamination poses significant risks to animal and public health, and occupational safety. These settings frequently host a wide variety of potentially pathogenic microorganisms, including *Staphylococcus aureus*, *Enterococcus spp.*, and *Escherichia coli*, introduced through animal patients, their owners, veterinary staff, equipment, and even air circulation. Although biosafety practices and aseptic protocols are routinely applied, their effectiveness can vary depending on the facility's infrastructure, staff compliance and training, and local environmental conditions. While most existing studies emphasize hospital-acquired infections in human healthcare, there is a notable knowledge gap regarding microbial persistence, contamination patterns, and AMR in animal care facilities. In this line, this work aims to evaluate the environmental/fecal contamination indicators, namely *Staphylococcus spp.*, *Enterococcus spp.* and *E. coli*, present in clinical and surgical environments of pet VCCs in Northern Portugal. **Materials and Methods:** Across eight VCCs, a systematic sampling was conducted, covering both general consultation rooms and surgical rooms. In each setting, five previously selected sampling points were collected based on critical contact surfaces, such as door handles, floor, walls, examination tables, and equipment, using sterile swabs. Samples were collected before the use of the space, pre-enriched in buffered peptone water at a 1:10 ratio, and incubated at 37°C for 18h. Subsequently, 0.1 mL was plated onto specific culture media, Mannitol Salt agar for *Staphylococcus aureus*, Slanetz-Bartley agar and Kanamycin Esculin Azide agar for *Enterococcus spp.*, and MacConkey agar and Chromogenic Coliform agar for *E. coli*. Up to five typical colonies with distinct morphology from each sample were selected. **Results:** Among the 80 samples collected, 40 from consultation rooms and 40 from surgical rooms, 50 showed bacterial growth for *Staphylococcus spp.*, *Enterococcus spp.* and/or *E. coli*, yielding a total of 68 isolates. *Staphylococcus spp.* (41/68, 60%) were detected in 39 samples. Of these isolates, 23/41 (56%) were collected from consultation rooms, while 18/41 (44%) were from surgical rooms. *Enterococcus spp.* (13/68, 19%) were detected in 12 samples, including 7/13 (54%) isolates collected from surgical rooms and 6/13 (46%) from consultation rooms. *E. coli* (14/68, 21%) was detected in 13 samples. Of these isolates, 8/14 (57%) were collected from consultation rooms and 6/14 (43%) from surgical rooms. **Conclusions:** Environmental contamination, indicated by *Staphylococcus spp.* was the most prevalent, followed by *E. coli* and *Enterococcus spp.* as indicators of fecal contamination. The distribution of isolates between room types was relatively balanced, however, *Staphylococcus spp.* and *E. coli* were more frequently associated with consultation rooms, while *Enterococcus spp.* showed a slightly higher occurrence in surgical rooms. These findings highlight the need for improved hygiene practices, including personnel training, standardized protocols, correct dosage and adequate time for detergents/disinfectants, as well as regular microbial monitoring.

Funding
This research was funded by the CESPU-Cooperativa de Ensino Superior Politécnico e Universitário, under the BioClnVet-GI2-CESPU-2025 project, and the 1H-TOXRUN of the University Institute of Health Sciences (IUCS-CESPU), and from FCT/MCTES for the national funds (UIDB/50006/2020 DOI 10.54499/UIDB/50006/2020, UIDP/50006/2020, UIDB/04378/2020 and LA/P/0140/2020).

Conflict of Interest Declaration
The authors declare no conflicts of interest.

PC13 Diagnostic contribution of the complete blood count in dogs and cats focus on degenerative and neoplastic conditions

Bisiaux T.[1]*, Barroso T.[2]

[1] IUCS-CESPU, Gandra Paredes, Portugal
[2] UCIBIO - Applied Molecular Biosciences Unit, University Institute of Health Sciences - CESPU (1H-TOXRUN, IUCS-CESPU), 4585-116 Gandra, Portugal.

*Correspondent author: A30499@gmail.com

ABSTRACT

Introduction and Aim: Since hematological analysers are widespread in veterinary practice, the Complete Blood Count (CBC) has become an essential routine exam used as a

diagnostic, prognostic, and monitoring tool. However, it is routinely interpreted in combination with blood smear, biochemistry, imaging, and other complementary exams. This systematic review aims to evaluate the diagnostic value of the CBC when interpreted exclusively alongside history and physical examination, with a focus on degenerative and neoplastic pathology in accordance with potential geriatric conditions. **Materials and Methods:** PRISMA guidelines with a study selection flow diagram were used to conduct this systematic review. A search was performed on three databases (PubMed, ScienceDirect, and Google Scholar), using combinations of keywords related to canine and feline species, CBC, diagnosis, and Boolean operators. Filters were applied for publication period (2015-2025), study type, species, and field when applicable. Studies were screened after duplicate removal. Inclusion criteria were: dogs and/or cats, explicit mention of CBC, and evaluation of CBC as a support/diagnostic tool. Exclusion criteria included: absence of support/diagnostic use, incorrect population, wrong study type or studies focused on prognosis/monitoring. Full-text screening excluded studies with non-informative, normal, or poorly reported CBC data. The extracted data included CBC parameters, clinical history, physical examination findings, and the authors' interpretations. Conditions were classified according to the VITAMIND framework (Vascular, Infectious/Inflammatory, Toxic, Autoimmune/Congenital, Metabolic, Iatrogenic, Neoplastic, Degenerative). The present analysis focused only on Neoplastic and Degenerative conditions. **Results:** A total of 68 studies were included, of which 11 corresponded to degenerative and neoplastic conditions. Most CBC alterations reflected non-specific systemic inflammatory responses rather than disease-specific mechanisms. Several CBC parameters and derived indices were significantly associated with specific conditions. Only a limited number of parameters demonstrated true discriminative potential, with cut-offs and potential diagnostic performance. When interpreted alongside anamnesis and physical examination, CBC findings contributed to prioritising differential diagnoses rather than establishing a definitive diagnosis. **Conclusions:** The CBC has limited standalone diagnostic value in degenerative and neoplastic conditions. Its clinical relevance increases when integrated with clinical data, where it can support differential diagnoses. Most hematological changes reflect non-specific systemic inflammation, and only a small subset of derived indices shows meaningful discriminative potential. Limitations are selection bias, heterogeneity among studies, and the limited number of included articles (11/68), which restrict these findings. Future research should investigate the prognostic and monitoring value of CBC-derived indices in degenerative and neoplastic conditions.

Funding
The authors received no specific funding for this work.

Conflict of Interest Declaration
The authors declare no conflicts of interest.

PC14 Chitosan as a sustainable biopolymer from crustacean waste: opportunities of food safety

Turosz E.[1]; Petrequin C.[1]; Loison G.[1]; David I.[1]; Afonso P.[1,2,3], Real H.[1,2,3]

[1] University Institute of Health Sciences (IUCS)-CESPU, Rua Central de Gandra, 4585-116 Gandra, Portugal
[2] Associate Laboratory i4HB - Institute for Health and Bioeconomy, University Institute of Health Sciences - CESPU, 4585-116 Gandra, Portugal.
[3] UCIBIO - Applied Molecular Biosciences Unit, Translational Toxicology Research Laboratory, University Institute of Health Sciences (1H-TOXRUN, IUCS-CESPU), 4585-116 Gandra, Portugal.

*Correspondent author: a31928@alunos.cespu.pt

ABSTRACT

Introduction and Aim: The increasing global production of plastic and the growing volume of seafood processing waste represent major environmental challenges. Crustacean processing generates large quantities of shells, which may account for up to 70% of total biomass and are often discarded, causing environmental pollution and sanitary risks. Chitosan, a natural polysaccharide derived from chitin present in crustacean shells, has emerged as a promising biodegradable biopolymer. The aim of this study was to review recent scientific literature on the production of chitosan from crustacean waste, focusing on extraction methods, physicochemical properties, industrial applications, and current limitations to large-scale implementation. **Materials and Methods:** A literature review was conducted between October 1 and December 11, 2025, using the scientific databases PubMed®, ScienceDirect®, and Google Scholar®. Search strategies included the keywords "shrimp shell", "chitosan", "food packaging", "bioplastic", "chitin", "recycling", and/or "plastic". Preference was given to articles published after 2020. The selected studies were analysed to identify key extraction techniques, as well as the functional properties and applications of chitosan-based materials. **Results:** Following screening based on relevance and recency, a total of eight scientific articles were selected for qualitative analysis. Chitosan presents several advantageous properties, including biodegradability, biocompatibility, non-toxicity, and intrinsic antimicrobial activity. These characteristics make it suitable for the development of edible films and biodegradable food packaging. Chitosan-based biofilms demonstrate good mechanical strength and low permeability to gases, contributing to the preservation of food products. Studies have shown that chitosan coatings can extend the shelf life of fresh foods by reducing microbial contamination and maintaining sensory qualities. Additionally, the valorisation of crustacean shells into chitosan contributes to waste reduction and supports circular economy strategies. **Conclusions:** Chitosan is a sustainable and promising biopolymer. It is derived from chitin present in crustacean shell waste and therefore provides a potential solution to the urgent need for alternatives to conventional plastics. The valorisation of marine waste, transforms a pollution problem into high-value products, aligning with the principles of the circular economy. It is a natural polysaccharide that is non-toxic, biocompatible, and biodegradable, with a strong film-forming capacity and good mechanical properties. Chitosan-based films can extend the shelf life of food products through antimicrobial activity while helping maintain freshness and texture. Despite its potential, large-scale industrial adoption still requires

overcoming several challenges. Current extraction methods (deproteinization and demineralization) and deacetylation processes rely on aggressive reagents and are energy intensive. Furthermore, chemical deacetylation may lead to a high degree of depolymerization, reducing the molecular weight and mechanical strength of the resulting bioplastic. In addition, the establishment of a structured supply chain for the collection and homogeneous pre-treatment of shell waste is necessary. Chitosan therefore represents an effective ecological solution for the production of biofilms. In the future, its development may rely on the implementation of marine biorefineries using more sustainable and environmentally friendly extraction processes, enabling the recovery of all shell components, ensuring long-term industrial viability, and contributing directly to the United Nations Sustainable Development Goals.

Funding
Not applicable.

Conflict of Interest Declaration
The authors declare no conflicts of interest.

PC15 Electropermeabilization as the basis of electrochemotherapy in veterinary oncology

Salazar M.[1]*, Queiroga F.[1]

[1] University of Trás-Os-Montes e Alto Douro, Vila Real, Portugal.

*Correspondent author: martafsalazar@gmail.com

ABSTRACT

Introduction and Aim: The lifespan of companion animals has significantly increased due to advancements in veterinary medicine and elevated standards of animal care. Consequently, age-related diseases, particularly cancer, have become more prevalent in veterinary patients. Currently, cutaneous and subcutaneous tumours represent the most frequently diagnosed neoplasms in dogs and cats, therefore benefiting from effective local treatments that preserve quality of life. Electrochemotherapy (ECT) is an emerging therapeutic modality that combines the administration of cytotoxic agents with the application of controlled electric pulses, allowing a transient increase in cell membrane permeability known as electropermeabilization. This process enhances the intracellular uptake of otherwise poorly permeant chemotherapeutic drugs such as bleomycin and cisplatin. This review aims to synthesise current scientific knowledge on the biophysical mechanisms underlying electropermeabilization and their relevance to the clinical application of ECT in veterinary oncology. **Materials and Methods:** A review of the relevant scientific literature on electropermeabilization and ECT in veterinary and comparative oncology was conducted. Scientific databases were searched using keywords including "electropermeabilization", "electroporation", "electrochemotherapy", "cell membrane pore formation" and related terms. Experimental, clinical and review articles describing the biophysical basis of membrane permeabilization and its therapeutic implications were considered. The selected studies were critically analysed to synthesise current understanding of electropermeabilization and assess its implications for veterinary clinical practice. **Results:** In the context of ECT, the literature describes electropermeabilization as a reversible biophysical phenomenon induced by the application of short-duration, high-voltage electric pulses, which transiently increase the transmembrane potential and lead to the formation of aqueous hydrophilic pores within the phospholipid bilayer. This temporary permeabilization allows cytotoxic agents with limited membrane permeability to enter tumour cells more efficiently, markedly enhancing their intracellular concentration and therapeutic efficacy. In addition to facilitating drug uptake, electropermeabilization exerts complementary antitumour effects, including modulation of blood flow and stimulation of systemic immune responses. Differences in membrane characteristics and proliferative activity between neoplastic and normal cells are thought to contribute to the relative selectivity of the treatment. **Conclusions:** Electropermeabilization represents the fundamental mechanism underlying the therapeutic efficacy of ECT. A comprehensive understanding of this biophysical phenomenon is essential to optimise treatment protocols and ensure its safe clinical application in veterinary practice.

Funding
Not applicable.

Conflict of Interest Declaration
The authors declare no conflicts of interest.

PC16 Clinical applications and the diagnostic and prognostic value of the NT-proBNP biomarker in myxomatous mitral valve disease in dogs: a review of current evidence

Paulo A.[1*], Oliveira T.[1], Afonso P.[1,2]

[1] IUCS – University Institute of Health Sciences, CESPU, Paredes, Portugal
[2] 1H-TOXRUN – One Health Toxicology Research Unit, Avenida Central de Gandra, n.º 1317, 4585-116 Gandra, Portugal.

*Correspondent author: a31934@alunos.cespu.pt

ABSTRACT

Introduction and Aim: Heart disease affects around 10% of dogs in clinical practice, with Myxomatous Mitral Valve Disease (MMVD) being the most prevalent condition (accounting for 75% of cases), followed by dilated cardiomyopathy. In this context, the NT-proBNP biomarker stands out among biomarkers as the most reliable diagnostic tool, as it is secreted in response to myocardial stretching and pressure overload. This peptide results from the cleavage of proBNP in quantities equivalent to the active fragment (C-BNP). Due to its stability and long half-life, NT-proBNP has become established in clinical practice through rapid assays. This review aims to analyse the current knowledge and reference values of this biomarker in canine cardiology. **Materials and Methods:** A literature review was conducted using articles published between 2016 and 2026, with the search terms: "NT-proBNP", "myxomatous mitral valve disease" and "dogs". Prospective studies and systematic reviews were selected that established correlations between plasma concentrations, echocardiographic parameters, radiographic indices and survival times. **Results:** NT-proBNP enables initial screening, with a cut-off value of >505.65

ρmol/L used to distinguish dogs with MMVD from healthy individuals (sensitivity 76.7%, specificity 89.5% and AUC 0.862). The biomarker also allows for the differentiation of asymptomatic and symptomatic patients with the suggested cut-off value >787.65 ρmol/L (sensitivity 78.28%, specificity 72.55% and AUC 0.792). The literature indicates that the combination of a murmur of grade ≥ 3/6, a vertebral heart size (VHS) ≥ 11.5, and NT-proBNP > 1100 ρmol/L suggests the presence of clinically relevant cardiomegaly. In addition to echocardiography, an NT-proBNP concentration > 1500 ρmol/L associated with an LA:Ao ratio > 2.1 and a peak E (maximum early transmitral velocity) > 1 m/s correlates with an increased risk of heart failure or cardiac death. In terms of prognosis, the DELAY study demonstrated a survival difference of 187 days between dogs with high and low concentrations. Furthermore, the biomarker shows a direct haemodynamic correlation with enlargement of the left atrium and ventricle. Recently, the use of an NT-proBNP-guided treatment algorithm has been shown to reduce plasma concentrations, improving the management of heart failure. **Conclusions:** Although NT-proBNP is less sensitive to rapid haemodynamic changes than ANP and is influenced by comorbidities such as hypertension, NT-proBNP remains a valuable tool. Its integration into routine clinical practice, alongside echocardiography, significantly improves diagnostic accuracy and prognostic prediction in canine heart disease.

Funding
Not applicable.

Conflict of Interest Declaration
Not applicable.

PC17 Geriatric polypharmacy: a 4-step algorithm to break the prescription cascade

Ponte R.[1]*, Afonso P.[1,2,3], Barroso T.[1,2,3]

[1] CESPU – Cooperativa de Ensino Superior Politécnico e Universitário, CRL, Paredes, Portugal.
[2] Associate Laboratory i4HB – Institute for Health and Bioeconomy, University Institute of Health Sciences – CESPU, 4585-116 Gandra, Portugal.
[3] UCIBIO – Applied Molecular Biosciences Unit, Translational Toxicology Research Laboratory, University Institute of Health Sciences (1H-TOXRUN, IUCS-CESPU), 4585-116 Gandra, Portugal.

*Correspondent author: a31718@alunos.cespu.pt

ABSTRACT

Introduction and Aim: Polypharmacy is frequent in geriatric animals due to multimorbidity, increasing the risk of adverse effects, clinically relevant interactions, and decreased therapeutic adherence. In geriatrics, the so-called "prescription cascade" is common; this occurs when the adverse effect of a drug is interpreted as a new clinical condition, leading to the introduction of additional medication. This phenomenon has a significant impact on the animal's quality of life and associated healthcare costs. The objective of this work is to synthesise current evidence and recommendations on pharmacological safety in geriatrics and to propose a structured and feasible protocol for therapeutic review, phased deprescription, and clinical monitoring. **Materials and Methods:** Narrative review focused on geriatric guidelines and pharmacovigilance literature based on clinical records and recommendations for prescribing in polymedicated patients. From this synthesis, a 4-step algorithm for application in geriatric clinical practice was developed: 1. Complete reassessment of drugs and supplements. 2. Identify "red flags". 3. Screening for interactions and contraindications. 4. Therapeutic planning with goals, timelines, and deprescription criteria. **Results:** 1. Complete reassessment of drugs and supplements: It is essential to perform a detailed record of everything the animal ingests, including prescription drugs, over-the-counter products, and nutraceuticals, specifically questioning the owner about the use of "natural" products. Substances such as St. John's wort and S-adenosylmethionine can precipitate serotonin syndrome, especially when combined with drugs frequently used in geriatric patients, such as selective serotonin reuptake inhibitors, tricyclics, or monoamine oxidase inhibitors. 2. Identify "red flags": Monitor therapeutic duplications, inadequate doses, intended duration, and masked symptoms. Anxiety is characteristic of canine cognitive dysfunction, but it can be exacerbated by chronic pain. Implementing effective multimodal analgesia can, in many cases, allow for the deprescription or reduction of psychotropic drugs. 3. Screening for interactions and contraindications: The use of non-steroidal anti-inflammatory drugs in cats with chronic kidney disease requires increased caution and should be avoided in unstable, dehydrated, or hypotensive animals. Monitoring should include creatinine, symmetric dimethylarginine, and urine protein-to-creatinine ratio, always ensure adequate hydration and haemodynamic stability. 4. Therapeutic planning: Goals should be individualised, focusing on quality of life, pain control, improved mobility, and stabilisation of sleep-wake cycles (1-2). The general reassessment of the geriatric patient should occur every 6-12 months. Therapy should be suspended in the presence of gastrointestinal signs, renal insufficiency (changes in creatinine/SDMA/UPC, dehydration, or hypotension), or if liver enzymes (ALT/AST) reach 2-3 times the upper limit. The minimum effective dose should be favoured through gradual reduction, using validated tools such as the feline musculoskeletal pain index or the canine dementia scale. In the event of owner overload, treatment should be simplified, maintaining the essentials for comfort, such as analgesia and sleep quality. **Conclusions:** Geriatric polypharmacy must be addressed as an independent clinical problem, requiring a structured approach: review, simplify, and monitor. A standardised protocol can reduce adverse events, improve therapeutic adherence, and align treatment with quality of life. It is recommended to document, for each drug, the clinical indication, objective therapeutic target, intended duration, monitoring plan, and deprescription criteria.

Funding
No funding was received for this work.

Conflict of Interest Declaration
None declared.

PC18 Corneal transplantation as a therapeutic approach for corneal staphyloma in a dog

Guimarães T.[1,2,3]*, Pinto M.[1], Osório A.[1], Costa C.[1], Hego C.[1], Varin L.[1], Cardoso K.[2,3]

[1] IUCS-CESPU, Gandra-Paredes, Portugal.
[2] Faculty of Medicine, University of Coimbra (FMUC), Coimbra, Portugal.
[3] Oncovision Care, Veterinary Oncology and Ophthalmology, Évora, Portugal.

*Correspondent author: tarcisio.guimaraes@iucs.cespu.pt

ABSTRACT

Case Description: A Shih Tzu dog with a traumatic corneal staphyloma in the left eye and was referred to the veterinary ophthalmology service due to severe ocular discomfort and persistent blepharospasm. Following clinical evaluation, surgical repair was performed via full-thickness corneal transplantation using a fresh homologous cornea preserved in Optisol-GS®. Prior to transplantation, the corneal lesion was measured using a Castroviejo caliper to determine the appropriate trephine size. The donor cornea was shaped to be 0.5 mm larger than the recipient cornea. The graft and recipient cornea were sutured using a simple interrupted pattern with 10-0 polyglactin suture. The anterior chamber was filled with BSS solution, maintaining a small air bubble, and the absence of leaks was confirmed. Ocular surface protection was achieved by temporary tarsorrhaphy and a hydrogel silicone contact lens. The postoperative protocol included antibiotics and steroidal anti-inflammatories systemics, as well as antibiotics, protease inhibitors, anticholinergics, and calcineurin inhibitors topicals. Ten days after transplantation, the tarsorrhaphy and contact lens were removed, revealing a vascularised a graft, without sodium fluorescein penetration. Topical corticosteroids and lubricants were prescribed. By day 21, the homologous cornea was integrated, with slight vascularisation and graft opacification, while vision was preserved. The dog was discharged from clinical with recommendations for ongoing regular ophthalmic follow-up. **Discussion:** Corneal transplantation, using fresh or preserved tissue, for full-thickness defects, restores tectonic integrity and preserves visual function in most cases, even in the presence of severe anatomical complications. Graft opacification and vascularisation, common in dogs due to immune response, can be mitigated with appropriate therapeutic management. In the case presented, fresh homologous corneal transplantation was effective in preserving vision and repairing corneal staphyloma.

Funding
Not applicable.

Conflict of Interest Declaration
Not applicable.

PC19 Hypertonic therapy for corneal oedema secondary to endothelial dystrophy in a dog

Fidelix C.[1], Le Gall M.[2], Tur E.[2], Cros E.[2], Gherardi C.[2], Gomes de Freitas E.[2], Cardoso K.[3], Guimarães T.[2,3]

[1] Qualittas Institute of Postgraduate Education, São Paulo, Brazil
[2] IUCS-CESPU, Gandra-Paredes, Portugal.
[3] Oncovision Care, Veterinary Oncology and Ophthalmology, Évora, Portugal.

*Correspondent author: tarcisio.guimaraes@iucs.cespu.pt

ABSTRACT

Case Description: A 10-year-old spayed mixed-breed female dog was consulted with progressive bilateral corneal opacity for approximately one year, with worsening in the last month. Previous treatments included antibiotics and topical cyclosporine, with no observed clinical benefit, and were discontinued. It was still receiving topical corticosteroids without significant improvement. Slit-lamp examination revealed diffuse corneal oedema, with small areas of perilimbal pigmentation and altered corneal curvature with a bulging appearance, particularly in the right eye. The Schirmer tear test, intraocular pressure, ocular ultrasonography and haematological and biochemical test, showed to be within normal physiological conditions. There were no signs of inflammation or ocular discomfort, and the sodium fluorescein test confirmed the integrity of the corneal epithelium. Based on the clinical history and the ophthalmological examination findings, the corneal oedema was attributed to endothelial dysfunction; therefore, the use of a 5% sodium chloride hypertonic solution was considered for topical treatment, every six hours. Ten days after the initiation of treatment, no ocular discomfort was observed and there was a significant reduction in the diffuse corneal oedema, became restricted to the central corneal area. How the progression of oedema may occur, additional surgical therapy using a conjunctival flap (Gundersen flap) was recommended; however, the owner opted to maintain pharmacological treatment. Therefore, the use of sodium chloride eye drops was continued four times daily, with regular re-evaluations every 60 days. **Discussion:** Treatment with 5% sodium chloride proved effective in reducing corneal oedema due to its hyperosmotic effect, which promotes the removal of fluid from the corneal stroma. Although this therapy does not reverse endothelial dysfunction, it may provide clinical improvement and symptomatic control of the disease. Considering the potential progression of the condition, additional surgical approaches may be required. Thus, the use of a topical hypertonic solution represents a conservative therapeutic alternative for the management of corneal oedema in dogs with endothelial cell dystrophy.

Funding
Not applicable.

Conflict of Interest Declaration
Not applicable.

PC20 Fluorescence guided neurosurgery for intracranial neoplasm in veterinary practice

Malherbe S.[1*], Alvites R.[1,2,3,4]

[1] IUCS- University Institute of Health Sciences, CESPU, Paredes, Portugal
[2] Departamento de Clínicas Veterinárias, Instituto de Ciências Biomédicas de Abel Salazar (ICBAS), Universidade do Porto (UP), Porto, Portugal
[3] Laboratório Associado para a Química Verde (LAQV) da Rede de Química e Tecnologia (REQUIMTE), Instituto de Ciências, Tecnologias e Agroambiente da Universidade do Porto (ICETA-UP), Porto, Portugal5 Associate Laboratory for Animal and Veterinary Science (AL4AnimalS), Lisboa, Portugal.
[4] Associate Laboratory for Animal and Veterinary Science (AL4AnimalS) Lisboa, Portugal.

*Correspondent author: a31929@alunos.cespu.pt

ABSTRACT

Introduction and Aim: Intracranial neoplasms represent 2 to 5% of all cancer in dogs and around 2% of cancer in cats. These tumors affect primarily geriatrique animals. Indeed meningiomas are commonly diagnosed around 9-11 years in both species, whereas gliomas can appear between 6 to 9 years olds in dogs. The achievement of a complete excision with clean margins remains challenging due to tumor location and the difficulty of distinguishing neoplastic tissue from normal brain parenchyma. Fluorescence-guided neurosurgery, well documented in human medecine, is currently under development in veterinary practice. The aim of this work is to present different fluorescent markers that may help improve the complete excision of intracranial neoplasms in small animal practice. **Materials and Methods:** The articles were selected using the preferred reporting items for systematics reviews and meta-analyses (PRISMA) methodology and websites such as Pubmed, ScienceDirect, Wiley Online Library and Springer. Articles published before 2017 were rejected. The key-words used were «fluorescence guided neurosurgery», «veterinary», «dog», «cat», «canine», «feline», «Indocyanine Green», «5-aminolevulinic acid», «fluorescein sodium», «meningioma», «glioma». **Results:** Clinical and experimental studies have shown that fluorescence-guided surgery drastically improves tumor identification, the rate of gross total resection (GTR) and the outcomes for the patient. While initial protocols and dosage were established in human medecin, veterinary applications often require adjustments. In humans, cats, and dogs, the 5-aminolevulinic acid (5-ALA) targets intracellular tumoral metabolism, offering high specificity (89-100%) for high-grade gliomas (HGG) and meningiomas. The sodium fluorescein (FS) act by identifying blood-brain barrier (BBB) lesions. However, it is less specific as it may also highlight edema or peritumoral inflammation. In dogs, it has identified gliomas, sarcomas and meningiomas, though adverse effects such as vomiting and benign coloration of the skin, mucous membranes, and urine have been noted. Finally, indocyanine Green (ICG), frequently used via the second window ICG technique (SWIG), highlights tumor permeability and the enhanced permeability and retention effect (EPR). This approach allows for transdural visualization through to the near-infrared (NIR) imaging, providing high sensibility (98%) despite the lack of specificity (39-45%). **Conclusions:** While 5-ALA, FS, and ICG utilize distinct mechanisms to improve the GTR of intracranial neoplasms, veterinary clinical data remains limited compared to human medicine. Future research is essential to standardize these protocols and further explore their integration with multimodal therapies like radiotherapy.

Funding
Not applicable.

Conflict of Interest Declaration
Not applicable.

PC21 Exploring Staphylococcus species by MALDI-TOF-Mass spectrometry method in companion animals with infectious dermatitis

Cellier L.[1,*], Guimarães H.[1], Campos C.[1,2,3], Barradas P.[1,4,5], Miranda C.[1,4,5,6]

[1] University Institute of Health Sciences, Cooperativa de Ensino Superior Politécnico e Universitário (IUCS-CESPU), Avenida Central de Gandra 1317, 4585-116 Paredes, Portugal
[2] Instituto Português de Oncologia do Porto Francisco Gentil, Rua Dr. António Bernardino de Almeida, 4200-072 Porto, Portugal
[3] Escola Superior de Saúde, Instituto Politécnico do Porto, Rua Dr. António Bernardino de Almeida, 4200-072 Porto, Portugal
[4] UCIBIO—Applied Molecular Biosciences Unit, University Institute of Health Sciences (1H-TOXRUN, IUCS-CESPU), Avenida Central de Gandra 1317, 4585-116 Paredes, Portugal
[5] Associate Laboratory i4HB - Institute for Health and Bioeconomy, University Institute of Health Sciences, CESPU, 4585-116 Gandra, Portugal
[6] LAQV-REQUIMTE—Associated Laboratory for Green Chemistry, University NOVA of Lisbon, 1099-085 Caparica, Portugal.

*Correspondent author: a30486@alunos.cespu.pt

ABSTRACT

Introduction and Aim: Bacterial dermatitis in pets, in particular dogs and cats, is a complex inflammatory skin condition, involving multiple causes and clinical manifestations, including redness, itching, lesions, scaling, and discharge. This condition has gained increasing relevance in recent years, mainly due to the rise of antimicrobial resistance, the potential cross-species pathogen transmission, zoonotic and environmental implications. When present, bacterial dermatitis is often caused by Staphylococcus spp., particularly S. pseudointermedius in dogs, identified by traditional microbiological and biochemical methods. After bacterial isolation, Matrix-Assisted Laser Desorption/Ionization Time-of-Flight (MALDI-TOF) mass spectrometry enables rapid diagnostic and helps guide treatment decisions. A bacterial colony is placed on a target plate with a matrix solution and analyzed by laser ionization. The resulting protein mass spectrum is then compared with a reference database to identify the bacterial species. This study aims to detect the presence of Staphylococcus species by MALDI-TOF mass spectrometry, in companion animals presenting signs of dermatitis. **Materials and Methods:** A total of 46 skin swabs were collected, of which 44 were obtained from dogs and 2 from cats, showing clinical signs of infectious dermatitis, between September 2025 and January 2026. Most animals presented with pruritus at the time of sampling, with lesions located on the paws, abdomen, ears, or face, characterized by alopecia, crust and erythema. The samples were plated on mannitol salt agar. Typical colonies (one to two per sample) were sub-cultured on brain heart infusion agar and stored for further species identification by MALDI-TOF mass spectrometry method. **Results:** Forty-nine presumptive Staphylococcus isolates showing growth on mannitol salt agar, were obtained from 28 (57.1%) samples. One isolate (28/49) per positive sample was selected for identification by MALDI-TOF mass spectrometry, of which 18 (64.3%) isolates were identified as Staphylococcus. Among the

identified staphylococcal isolates, the following species were detected: *Staphylococcus pseudointermedius* (n=14, 77.8%), *Staphylococcus felis* (n=2, 14.3%), *Staphylococcus aureus* and *Staphylococcus xylosus* (n=1, 7.1% each). Most of these isolates were obtained from dogs (n=16, 88.9%), predominantly *S. pseudointermedius* (14/16, 87.5%). The majority were from males (n=9, 56.3%), and adults (n=14, 87.5%) and the French Bulldog was the most represented breed (n=5, 31.3%). Two isolates (11.1%, S. felis) were collected from one male and one female cats, both from adults, neutered and of European breed. **Conclusions:** According to this study, the predominance of Staphylococcus species, particularly Staphylococcus pseudointermedius, was high in infectious dermatitis cases in companion animals, despite the limited number of samples. These results highlight the value of advanced diagnostic methods, such as MALDI-TOF mass spectrometry for rapid and accurate pathogen identification in veterinary dermatology. The detection of multiple Staphylococcus species, including Staphylococcus aureus and Staphylococcus felis, also highlights potential zoonotic implications associated with these infections. Within a One Health approach, pathogen identification supports more targeted antimicrobial use, which is essential to reduce the development of antimicrobial resistance. Overall, these findings show the importance of accurate microbiological diagnostics to improve treatment strategies and clinical outcomes in companion animals while contributing to better public and environmental health.

Funding
This work was funded by the 1H-TOXRUN of the University Institute of Health Sciences (IUCS-CESPU), and from FCT/MCTES for the national funds (UIDB/50006/2020 DOI 10.54499/UIDB/50006/2020, UIDP/50006/2020, UIDB/04378/2020 and LA/P/0140/2020).

Conflict of Interest Declaration
The authors declare no conflicts of interest.

PC22 Q fever in Portugal: epidemiological analysis 2019-2023 in the European context and a One Health perspective

Campos M.[1]*; Maia M.[1]; Dias J.[1]; Queiroz M.[1]; Sá J.[1]; Osório A.[1]; Afonso P.[1,2]; Real H.[1,2]

[1] IUCS – University Institute of Health Sciences, CESPU, Paredes, Portugal
2 1H-TOXRUN – One Health Toxicology Research Unit, Gandra, Portugal.

*Correspondent author: a31298@alunos.cespu.pt

ABSTRACT

Introduction and Aim: Q fever is a zoonosis caused by *Coxiella burnetii*, a highly resistant obligate intracellular bacterium with worldwide distribution and significant public health relevance at the human-animal-environment interface. Transmission occurs predominantly via inhalation of contaminated aerosols, placing farmers, veterinarians, slaughterhouse workers, and other occupational groups in close contact with livestock at particularly elevated risk. In Portugal, serological and microbiological evidence in domestic ruminants, wildlife, and high-risk occupational cohorts indicates the country is endemic, despite consistently low levels of notified human clinical cases. This study aimed to describe the recent epidemiological situation of Q fever in the European Union (EU) and in Portugal between 2019 and 2023, compare notification patterns across both levels and discuss potential explanations for the observed discrepancies. **Materials and Methods:** Epidemiological data on confirmed Q fever cases were retrieved from the official website of the European Food Safety Authority (EFSA) on 18 November 2025. Annual mean temperature anomaly data were extracted from the Copernicus Climate Change Service (C3S) Global Climate Highlights 2024 report. Notification rates were calculated as confirmed cases per 100,000 inhabitants and compared between Portugal and the EU average over the study period. **Results:** Between 2019 and 2023, the EU recorded approximately 470-1,020 confirmed Q fever cases annually, with an overall notification rate ranging from 0.11 to 0.20 per 100,000 inhabitants. Portugal consistently reported lower absolute case counts, between 18 and 33 cases per year, yet presented notification rates between 0.17 and 0.32 per 100,000 inhabitants, peaking in 2019 and reaching a minimum in 2021, followed by a gradual recovery through 2023. Regarding the mean annual temperature anomaly, all years within the study period recorded positive values relative to the historical reference average. After a marked peak of +1.37 ºC in 2020, a sharp decline was observed in 2021 (to +0.09 ºC), followed by a recovery to +0.92 ºC in 2022 and +1.13 ºC in 2023. **Conclusions:** Despite remaining among the least frequently notified zoonoses in both the EU and Portugal, Q fever data for 2019-2023 suggest persistent structural underdiagnosis, reinforced by the known discordance between notification rates and seroprevalence evidence in animal reservoirs and at-risk human populations. The observed decline in notification rates in 2021, coinciding with the peak of COVID-19 control measures, is likely attributable to a combination of reduced real exposure, owing to widespread use of masks and other personal protective equipment (PPE), decreased mobility, and curtailed rural activities, alongside increased underdiagnosis related to reduced laboratory investigation of atypical pneumonias and diagnostic prioritization of COVID-19; the subsequent recovery in 2022-2023 supports a transient rather than structural effect on baseline risk. These findings reinforce the critical importance of sustained surveillance, One Health-integrated approaches, and strict adherence to PPE protocols among occupational groups exposed to potentially infected livestock and their environments.

Funding
Not applicable.

Conflict of Interest Declaration
The authors declare no conflicts of interest.

PC23 Case Report: osteomyelitis in a 6-month-old female rabbit, a relatively rare diagnosis with few reports in this specie, requiring lengthy tretament

Lazare C.[1]*, Freitas F. [1], Afonso P.[1]

[1] CESPU (IUCS), Paredes, Portugal.

*Correspondent author: a31925@alunos.cespu.pt

ABSTRACT

Case Description: Cenourinha is a 6-month-old lop-eared rabbit brought in for consultation due to lameness. An initial anti-inflammatory treatment (based on meloxicam) was administered at home, with close monitoring; however, as his condition worsened. A complete blood count and biochemistry were performed, along with radiographic examination (dorsoventral and lateral projections of the carpo-humeral region). The radiographic examination showed osteolysis with cortical involvement and periosteal reaction, showing an aggressive bone lesion, suggestive of osteosarcoma rather than osteomyelitis. A biopsy was performed by an orthopaedic surgeon, followed by histopathological analysis, bacterial culture and antibiogram. The rabbit was treated empirically with trimethoprim-sulfamide while awaiting the antibiogram results. In the meantime, the biopsy confirmed the diagnosis of osteomyelitis. The initial culture results revealed the presence of *Streptococcus spp*. sensitive to enrofloxacin. The treatment was therefore changed, and a week later new results were received, revealing the presence of *Pasteurella multocida*, sensitive to doxycycline, demanding treatment change. The curing process had a surgical complication involving an abscess and suture dehiscence. Complications happened beyond these various steps, which show the challenge of treating a severe bacterial infection. Details specifying the differences in lagomorph medicine have been provided throughout the report. **Discussion:** The aim of this case report was to demonstrate the difficulty in determining a diagnosis for orthopaedic disorders in rabbits, as well as the difficulty in monitoring treatment for an aggressive osteomyelitis. The use of antibiotics must be carefully considered in rabbits, as they can cause potentially fatal dysbiosis. In this case, osteomyelitis may have originated from a pre-existing or concurrent *Pasteurella multocida* infection, which is an opportunistic commensal of the rabbit's respiratory and oropharyngeal flora, by a subsequent hematogenous or contiguous spread to bone, potentially compounded by unnoticed local trauma or a state of immunosuppression or stress, that facilitated lesion progression and infection. Managing such an infection, despite rigorous testing, can be complicated because this species is less well known and requires a financial investment from the owner for all procedures and home care. The possibility of amputation in the event of treatment failure, even if the clinical condition of the osteomyelitis has improved, cannot be ruled out. Veterinary medicine for rabbits is a field that is just waiting to be explored, documented and referenced to help veterinarians in their work, particularly if they are normally used to working with dogs and cats. This abstract has been written as a supplement to my research and the drafting of my thesis around this thematic.

Funding
Not applicable.

Conflict of Interest Declaration
Not applicable.

PC24 Live animal markets: a pandemic waiting to happen – preliminary results

Amélie V.[1], Angeline T.[1*], Romain P.[1], Afonso P.[1,2,3], Real H.[1,2,3]

[1] University Institute of Health Sciences, CESPU, crl I Rua Central de Gandra, 1317 I 4585-116 Gandra PRD I Portugal
[2] Associate Laboratory i4HB - Institute for Health and Bioeconomy, University Institute of Health Sciences - CESPU, 4585-116 Gandra, Portugal.
[3] UCIBIO - Applied Molecular Biosciences Unit, Translational Toxicology Research Laboratory, University Institute of Health Sciences (1H-TOXRUN, IUCS-CESPU), 4585-116 Gandra, Portugal.

*Correspondent author: a31926@alunos.cespu.pt

ABSTRACT

Introduction and Aim: Live animal markets are very common in many countries as part of the food supply chain. These markets represent critical interfaces between humans, domestic animals, and wildlife, creating favourable conditions for the emergence and spread of zoonotic diseases. Factors such as species diversity, close contact with humans, increased animal stress, and inadequate or poorly regulated hygiene practices may promote the emergence or modification of new or recurring pathogens. This study aims to understand the mechanisms by which live animal markets influence human health and to explore how these risks could be reduced. **Materials and Methods:** This work is based on the analysis of various studies conducted in several countries where live animal markets are significant. These studies examine zoonotic disease risks associated with these markets, including worker exposure to zoonotic viruses, airborne transmission in market environments, circulation of pathogens in animal supply chains, and existing gaps in hygiene, traceability, and governance. **Results:** The reviewed studies highlight several key findings: increased exposure of workers to zoonotic viruses, particularly influenza viruses; evidence of airborne transmission within market environments; silent circulation of pathogens along animal supply chains; and persistent shortcomings in hygiene, traceability, and governance. Socio-economic constraints have also been identified as a major barrier to the implementation of effective reforms. **Conclusions:** Live animal markets play an important socio-economic role but also represent significant risk factors for the emergence of zoonotic diseases. While some progress has been observed since the COVID-19 crisis, particularly in reducing wild animal consumption, these changes remain insufficient. Balancing the essential function of these markets with effective zoonosis prevention represents a major challenge and highlights the importance of the One Health approach.

Funding
Not applicable.

Conflict of Interest Declaration
Not applicable.

PC25 Risks associated with raw milk consumption: bacterial contamination

Soutif C.[1]*, Boissière A.[1], Pinel C.[1], Gomes de Freitas E.[1], Afonso P.[1,2,3], Real H.[1,2,3]

[1] University Institute of Health Sciences (IUCS), CESPU, Gandra, Portugal
[2] Associate Laboratory i4HB - Institute for Health and Bioeconomy, University Institute of Health Sciences - CESPU, 4585-116 Gandra, Portugal.
3 UCIBIO - Applied Molecular Biosciences Unit, Translational Toxicology Research Laboratory, University Institute of Health Sciences (1H-TOXRUN, IUCS-CESPU), 4585-116 Gandra, Portugal.

*Correspondent author: A31937@alunos.cespu.pt

ABSTRACT

Introduction and Aim: Milk production enables the survival of a large part of the world's population, and the European Union's milk market represents a significant part of its agricultural market. Moreover, the European Food Safety Authority reported that European consumers are increasingly interested in drinking raw milk. Still, it noted that consuming raw milk and its derivatives may pose a serious health risk, as raw milk is increasing demand. But still, this authority also reported that consuming raw milk and its derivatives may pose a serious health risk, as raw milk is a source of pathogenic bacteria. There are several risk factors for milk contamination at different stages of production, particularly on the farm, making farming practices a key factor in controlling and reducing bacterial contamination. **Materials and Methods:** Data collection was performed on PubMed, ScienceDirect, and the Food and Agriculture Organisation (FAO) platform during October and November 2025 using the following keywords: "raw milk", "contamination", "bacteria", "system production" and "cattle". For this research, only articles discussing bacterial contamination, published within the last 10 years and with a free access were included in our study. In addition, articles not written in English, French or Portuguese were excluded from our study. Finally, articles whose studies were conducted outside developed countries were also excluded. Only one book from FAO was included in our study. Thirteen articles and one book were therefore analysed to write this study. **Results:** Twelve articles and one book were therefore studied. The Brucellosis vaccine significantly reduces contamination of raw milk. Moreover, milk from cows fed contaminated feed has a higher bacterial contamination level. The results show that high refrigeration and a combination of heating and refrigeration significantly extend the shelf life of raw milk. Refrigeration has a lesser impact on Listeria monocytogenes. Moreover, antibiotic residues and high levels of E. coli have been detected in raw milk, and contamination of raw milk with Staphylococcus aureus and E. coli is higher in summer than in winter. The main source of contamination of raw milk remains the equipment used during milking, and sterilising the equipment can significantly reduce this phenomenon. **Conclusions:** Besides, when teat hygiene is rigorous, the tips of the teats are not the source of spore contamination in raw milk. Farming practices therefore play a key role in reducing bacterial contamination. However, some practices have a greater impact than others, with equipment and udder hygiene during milking being the most critical factors. To reduce economic risks associated with production losses due to contamination and the risk of consumers ingesting pathogenic bacteria, farmers are advised to follow good hygiene practices during milking rigorously.

Funding
Not applicable.

Conflict of Interest Declaration
Not applicable.

VETERINARY NURSING

PC26 Portuguese stray cats as potential reservoirs of *Giardia* and *Cryptosporidium*

Gomes-Gonçalves S.[1], Gomes-Sá S.[2], Figueiredo R.J.[1], Brito N.V.[2,3], Mesquita J.R.[1,4], Barradas P.F.[2,5]*

[1] ICBAS, School of Medicine and Biomedical Sciences, Porto, Portugal
[2] UCIBIO, Applied Molecular Biosciences Unit, University Institute of Health Sciences, IUCS-CESPU, Paredes, Portugal
[3] CISAS, Escola Superior Agrária, Instituto Politécnico de Viana do Castelo, Viana do Castelo, Portugal
[4] LAQV, REQUIMTE, Department of Chemistry and Biochemistry, Faculty of Sciences, Porto, Portugal
[5] CECAV - Veterinary and Animal Research Center, University of Trás-os-Montes e Alto Douro, Vila Real, Portugal.

*Correspondent author: patricia.barradas@iucs.cespu.pt

ABSTRACT

Introduction and Aim: *Giardia duodenalis* and *Cryptosporidium spp*. are important zoonotic protozoan parasites capable of causing significant morbidity in humans and animals worldwide. Cats may serve as potential reservoirs due to their proximity to humans; however, data on their prevalence in Portuguese feline populations remain scarce. This study assessed the occurrence and genetic diversity of *G. duodenalis* and *Cryptosporidium spp.* in sheltered and stray cats from northern Portugal. **Materials and Methods:** A total of 150 faecal samples were collected from three districts (Porto, Braga, and Viana do Castelo) between 2023 and 2025 using convenience sampling from animal shelters, welfare associations, and a municipal trap-neuter-return programme. Molecular detection was performed using qPCR and (semi-) nested PCR targeting the SSU-rRNA gene, followed by MLST for *G. duodenalis* and identification of *Cryptosporidium spp*. **Results:** *Giardia duodenalis* was detected in 4.0% (6/150) of samples by qPCR. *Cryptosporidium spp.* was detected in 0.7% (1/150) of samples, with molecular characterization identifying *C. felis*. **Conclusions:** This study provides baseline data on *G. duodenalis* and *Cryptosporidium spp*. occurrence in Portuguese cat populations.

Funding
This work was funded by the University Institute of Health Sciences (IUCS-CESPU, GIARDCat_GI2-CESPU-2023).

Conflict of Interest Declaration
The authors declare no conflicts of interest.

PC27 Detection of *Anaplasma spp.* in free-roaming cats

Morais E.[1,*,#], Oliveira J.[1,#], Rubim A.[1,#], Aleixo M.[1,#], Marques A.[1], Gomes S.S.[2], Barradas P.[2,3]

[1] Tâmega and Sousa School of Health Technologies, Cooperativa de Ensino Superior Politécnico e Universitário (IUCS-CESPU), Avenida Central de Gandra 1317, 4585-116 Paredes, Portugal
[2] UCIBIO, Applied Molecular Biosciences Unit, University Institute of Health Sciences, IUCS-CESPU, Rua Central de Gandra, 1317, 4585-116 Gandra PRD, Portugal
[3] CECAV - Veterinary and Animal Research Center, University of Trás-os-Montes e Alto Douro, Quinta de Prados, Vila Real 5000-801, Portugal.
*Correspondent author: erica.morais8@hotmail.com

[#] All authors contributed equally.

ABSTRACT

Introduction and Aim: Anaplasmosis is an emerging vector-borne zoonosis of increasing relevance in veterinary medicine, caused by obligate intracellular bacteria of the genus *Anaplasma*. These pathogens are primarily transmitted by ticks that show heightened activity in spring and summer months, specifically Ixodes species as the main vectors for *Anaplasma phagocytophilum* and *Rhipicephalus sanguineus* for *Anaplasma platys*. Stray cats represent a vulnerable and frequently overlooked population, potentially acting as reservoirs for various pathogens, including zoonotic agents. These animals often live in proximity to human settlements, increasing the risk of pathogen transmission to domestic pets and humans. Adult female cats are particularly relevant for epidemiological surveillance as they maintain colony stability and reproductive dynamics. This study aimed to determine the prevalence of *Anaplasma spp.* in adult female stray cats, captured within sterilisation programmes and subsequently returned to the outdoor environment through Trap-Neuter-Return (TNR) protocols. **Materials and Methods:** Fifty EDTA-blood samples were collected from adult female street cats at different time points: 12 in September 2025, 12 on 17 October 2025, and 26 in January 2026. Total genomic DNA was extracted using the NZY Tissue gDNA Isolation Kit according to the manufacturer's instructions. The presence of *Anaplasma* was investigated by molecular detection of 16S rRNA gene. PCR products will be purified and sequenced, and the obtained sequences will be analyzed using the Basic Local Alignment Search Tool (BLAST) to assess homology with reference sequences available in GenBank. **Results:** Two of the 50 samples tested positive for *Anaplasma spp.*, resulting in a prevalence of 4%. Both positive samples were from cats sampled in September 2025, with no detections in October 2025 or January 2026, suggesting a possible association with periods of higher tick activity. **Conclusions:** The presence of *Anaplasma spp.* in street cats suggests that these animals may contribute to the maintenance of tick-borne pathogens in the environment. Further studies with larger sample sizes and molecular characterization are needed to better understand the epidemiology of *Anaplasma* in feline populations.

Funding
This work was funded by the University Institute of Health Sciences (IUCS-CESPU, GenRick-GI2-CESPU-2025).

Conflict of Interest Declaration
The authors declare no conflicts of interest.

PC28 Molecular detection of *Rickettsia spp.* in ticks collected from dogs in manaus, Barzil

Oliveira B.[1,*,#], Sousa B.[1,*,#], Magalhães L.[1,*,#], Leitão S.[1,*,#], Marques A.[1]; Mesquita J.R.[2], Barradas P.[3,4]

[1] University Institute of Health Sciences, Cooperativa de Ensino Superior Politécnico e Universitário (IUCS-CESPU), Avenida Central de Gandra 1317, 4585-116 Paredes, Portugal
[2] ICBAS—School of Medicine and Biomedical Sciences, Porto University, 4050-313 Porto, Portugal
[3] UCIBIO, Applied Molecular Biosciences Unit, University Institute of Health Sciences, IUCS-CESPU, Rua Central de Gandra, 1317, 4585-116 Gandra PRD, Portugal
[4] CECAV - Veterinary and Animal Research Center, University of Trás-os-Montes e Alto Douro, Quinta de Prados, Vila Real 5000-801, Portugal.

*Correspondent author: a39604@alunos.cespu.pt

[#] All authors contributed equally.

ABSTRACT

Introduction and Aim: Tick-borne zoonotic diseases represent an increasing threat to public health, highlighting the importance of identifying the pathogens associated with these vectors. Spotted fever rickettsiosis is an emerging zoonotic disease with a global distribution, primarily transmitted by hard ticks (Acari: Ixodidae), which serve as vectors and reservoirs of *Rickettsia* and play a key role in maintaining and transmitting these obligate intracellular bacteria in nature. Considering the limited data on the prevalence of *Rickettsiae* in Manaus, this study aimed to detect *Rickettsia spp.* in ticks collected from dogs and to perform a phylogenetic analysis. **Materials and Methods:** Total genomic DNA from ticks (n = 126) was extracted using the NZY Tissue gDNA Isolation Kit according to the manufacturer's instructions. Molecular detection of *Rickettsia* was carried out on 21 DNA pools of ticks collected from domestic dogs by PCR amplification targeting a 420 bp fragment of the outer membrane protein B (*ompB*) gene. **Results:** A total of 126 ixodid ticks were examined in this study. Among the 21 DNA pools (each containing DNA from eight ticks), conventional PCR detected *Rickettsia spp.* in one pool (4.8%). PCR products will be purified and sequenced, and the obtained sequences will be analyzed using the Basic Local Alignment Search Tool (BLAST) to assess homology with reference sequences available in GenBank. **Conclusions:** The detection of Rickettsia DNA in tick pools collected from domestic dogs indicates the potential presence of rickettsial agents in the local tick population. Sequencing and phylogenetic analysis will be essential to determine the species involved and to better understand the epidemiological significance of these findings.

Funding
This work was funded by the University Institute of Health Sciences (IUCS-CESPU, GenRick-GI2-CESPU-2025).

Conflict of Interest Declaration
The authors declare no conflicts of interest.

PC29 Diagnostic and therapeutic approaches in canine stifle osteoarthritis: a literature review

Oliveira L.D.C.[1]; Vieira de Brito A.N.V.[2,3]; Paixão GMQ[1,4]

[1] Escola Superior Agrária, Instituto Politécnico de Viana do Castelo, Ponte de Lima, Portugal
[2] CESPU – Cooperativa de Ensino Superior Politécnico e Universitário, Gandra, Portugal
[3] Escola Superior Agrária, Instituto Politécnico de Viana do Castelo, Ponte de Lima, Portugal
[4] Instituto Politécnico de Bragança, Bragança, Portugal.

*Correspondent author: leonordaoliveira@ipvc.pt

ABSTRACT

Introduction and Aim: Osteoarthritis (OA) is a chronic, progressively disabling degenerative joint disorder characterized by cartilage damage, synovial inflammation, and changes in the periarticular tissues. In dogs, stifle osteoarthritis is commonly associated with cranial cruciate ligament rupture and patellar luxation, leading to joint instability and degeneration. Osteoarthritis is a common condition in older adults and a significant cause of pain and reduced mobility. The disease is particularly common in older dogs and represents a major cause of pain and reduced mobility. As no curative treatment exists, current management focuses on pain control and slowing disease progression. Recent advances in regenerative medicine and molecular diagnostics have improved understanding of the disease. The study aimed to review the literature on the pathophysiology, diagnostic evaluation, and therapeutic approaches for canine stifle osteoarthritis. **Materials and Methods:** A narrative literature review was conducted on five scientific articles addressing osteoarthritis in dogs. The selected studies included experimental research on synovial fluid changes, clinical research on regenerative therapies such as platelet-rich plasma (PRP) and stromal vascular fraction (SVF), and molecular research on the presence of bacterial DNA in osteoarthritis. Information regarding disease mechanism, diagnostic features, and treatment outcomes was analysed to identify current trends and therapeutic perspectives in canine osteoarthritis. **Results:** Osteoarthritis in the stifle joint of dogs is frequently associated with mechanical instability caused by cranial cruciate ligament (CCL) rupture. Experimental studies demonstrated that ligament transection induces inflammatory changes within the joint, including increased protein concentration, altered mucin clot quality, and increased cellularity in synovial fluid. These alterations may persist for several months following joint instability. Synovial fluid analysis is an important diagnostic tool in joint disease. Changes in viscosity, turbidity, cell count, and protein concentration help differentiate between septic arthritis, immune-mediated diseases, and degenerative joint diseases. Conventional management involves a multi-faceted approach including non-steroidal anti-inflammatory drugs, analgesics, weight management, rehabilitation therapy, and nutritional supplementation. Regenerative therapies have recently gained attention. Platelet-rich plasma therapy has shown promise as a potential therapy for osteoarthritis. The clinical benefits of platelet-rich plasma have shown promising clinical outcomes, including a reduction in lameness and pain in dogs unresponsive to conventional treatments. Stromal vascular fraction derived from adipose tissue has also demonstrated regenerative potential. However, although intra-articular injection of SVF has shown some improvement in clinical signs, objective improvements are limited and appear

temporary. Recent molecular studies have identified bacterial DNA in a considerable proportion of synovial fluid samples from dogs with stifle pathology. Although not associated with lesion type, bacterial DNA detection was correlated with osteoarthritis severity. **Conclusions:** Osteoarthritis in the stifle joint of the dog is a multifactorial problem involving mechanical instability, chronic inflammation, and intricate molecular mechanisms. Analysis of synovial fluid remains an important aspect in the evaluation of joint pathology. Conventional multimodal therapy remains the cornerstone of clinical management. Regenerative therapies such as platelet-rich plasma and stromal vascular fraction are emerging as adjunctive options; however, their long-term efficacy remains to be evaluated.

Funding
Not applicable.

Conflict of Interest Declaration
The authors declare no conflicts of interest.

PC30 The importance of aseptic technique in veterinary nursing during subcutaneous injections: a case of post injection subcutaneous abscess

Soares B.[1,2,*]; Alvites R.[1,3,4,5]; Buraco S.[1,2]

[1] CESPU - Cooperativa de Ensino Superior Politécnico e Universitário, CRL, Gandra, Portugal
[2] AniCura Centro Hospitalar Veterinário do Porto CHV, Porto, Portugal
[3] Departamento de Clínicas Veterinárias, Instituto de Ciências Biomédicas de Abel Salazar (ICBAS), Universidade do Porto (UP), Porto, Portugal
[4] Laboratório Associado para a Química Verde (LAQV) da Rede de Química e Tecnologia (REQUIMTE), Instituto de Ciências, Tecnologias e Agroambiente da Universidade do Porto (ICETA-UP), Porto, Portugal.
[5] Associate Laboratory for Animal and Veterinary Science (AL4AnimalS), 1300-477 Lisboa, Portugal.

*Correspondent author: beatrizsoares.vet@gmail.com

ABSTRACT

Case Description: A seven-year-old spayed female Doberman weighing 33.1 kg developed a subcutaneous abscess secondary to inadequate aseptic technique during the administration of Lokivetmab, a subcutaneous monoclonal antibody therapy used to manage canine atopic dermatitis. The dog was referred to AniCura Veterinary Hospital Porto after the owner detected a large, firm and mobile swelling in the dorsal cervical region, coinciding with the previous injection site. The patient also presented with localised oedema extending to the right pelvic limb and cranial abdominal region, likely associated with inflammatory involvement of the regional lymphatic drainage pathways, particularly the superficial cervical and axillary lymph nodes. Clinical examination revealed an alert patient with slightly congested mucous membranes, capillary refill time under two seconds, and an estimated dehydration of approximately 5%. These findings were likely associated with peripheral vasodilation and a systemic inflammatory response secondary to the infectious process. Body temperature was within normal limits (38.2 °C) and no abdominal discomfort was detected. Haematological analysis revealed marked leukocytosis (27.34 ×10⁹/L) characterised by pronounced neutrophilia (24.39 ×10⁹/L) and mild monocytosis (1.45 ×10⁹/L), consistent with an inflammatory response triggered by a bacterial infectious process. Initial diagnostic evaluation included fine-needle aspiration of the lesion, yielding sanguineous and purulent exudate, confirming the presence of a subcutaneous abscess. Following analgesic administration, a small surgical incision was performed to facilitate adequate drainage of the purulent material. The patient was hospitalised for close monitoring and received intravenous amoxicillin-clavulanic acid together with analgesic therapy. During hospitalisation, repeated drainage and lavage of the cavity with sterile 0.9% sodium chloride solution were performed to remove residual exudate and promote secondary intention healing. After two days of hospitalisation, the patient was discharged with oral amoxicillin-clavulanic acid and instructions for continued monitoring. At the follow-up consultation two weeks post-discharge, marked clinical improvement was observed, with complete resolution of the swelling and no evidence of further complications. **Discussion:** Subcutaneous abscess formation is not described as an adverse effect of Lokivetmab in the product's official prescribing information. This supports the hypothesis that the lesion was attributable to inadequate aseptic technique during injection rather than to the pharmacological action of the drug itself. This case highlights the critical importance of strict aseptic protocols during routine injectable procedures in veterinary practice. Proper skin preparation, the use of sterile materials and correct handling techniques are essential measures to mitigate the risk of bacterial contamination. Evidence from veterinary literature demonstrates that adherence to aseptic protocols significantly reduces microbial load and the risk of post-injection infections. From a veterinary nursing perspective, this case reinforces the essential role of veterinary nurses in ensuring correct asepsis and infection prevention during daily clinical procedures.

Funding
Not applicable.

Conflict of Interest Declaration
The authors declare no conflicts of interest.

PC31 Tick-borne *Ehrlichia spp.* in dogs from Manaus Brazil: a molecular surveillance study

Moutinho A.[1,*,#]; Casanova L.[1,#]; Pinto M. [1,#]; Almeida M.[1,#]; Marques A. [1]; Mesquita J.R.[2], Barradas P.[3,4], Soares B.[1,2,*]; Alvites R.[1,3,4,5]; Buraco S.[1,2]

[1] University Institute of Health Sciences, Cooperativa de Ensino Superior Politécnico e Universitário (IUCS-CESPU), Paredes, Portugal
[2] ICBAS—School of Medicine and Biomedical Sciences, Porto University, Porto, Portugal
[3] UCIBIO, Applied Molecular Biosciences Unit, University Institute of Health Sciences, IUCS-CESPU, Paredes, Portugal
[4] CECAV - Veterinary and Animal Research Center, University of Trás-os-Montes e Alto Douro,Vila Real, Portugal.

*Correspondent author: a39279@alunos.cespu.pt

[#] These authors contributed equally to this work.

ABSTRACT

Introduction and aim: Dogs are among the most important companion animals with a close association with human daily

life. Outdoor activities expose these pets to ticks, increasing humans' risk of zoonotic disease infection. Canine monocytic ehrlichiosis caused by *Ehrlichia canis* is among the most common tick-borne diseases affecting dogs worldwide. Rhipicephalus *sanguineus* sensu lato (s.l.) vectors this Gram-negative obligatory intracellular bacterium, which are the most common ticks infesting dogs worldwide. Indeed, the wide distribution of *E. canis* is associated with the ubiquitous distribution of tick vectors, which are highly adapted to urban environments in tropical and temperate regions. Although ehrlichiosis is considered endemic in several regions of Brazil, epidemiological data from Manaus remain scarce. The present study aimed to investigate the presence of *Ehrlichia spp.* in ticks collected from domestic dogs from Manaus, Brazil. **Materials and methods:** Ticks (n=21 pools) were collected from dogs during clinical examinations and preserved in 70% ethanol. Morphological identification was performed prior to laboratory analysis. Total genomic DNA extraction was conducted using the NZY Tissue gDNA Isolation Kit, following the manufacturer's instructions. Ticks were tested by Polymerase Chain Reaction (PCR) designed to amplify a 345 bp fragment of the 16S rRNA gene. **Results:** Of the 21 tick pools screened, three (14.3%) tested positive for *Ehrlichia spp.*. **Conclusions:** This study detected *Ehrlichia spp.* in ticks collected from domestic dogs in Manaus, Brazil. The findings suggest that ticks in the region may play an important role in the transmission of rickettsial pathogens, underscoring the need for continuous surveillance and further molecular characterization of circulating strains.

Funding
This work was funded by the University Institute of Health Sciences (IUCS-CESPU, GenRick-GI2-CESPU-2025).

Conflict of Interest Declaration
The authors declare no conflicts of interest.

PC32 Intervertebral disc disease in a French Bulldog: the role of postoperative rehabilitation

Carvalho M.[1,*,#], Ferreirinha P.[2,#], Rodrigues F.[1], Moreira J.[3], Bento F.[3], Lima N.R.[2,4,5]

[1] Polytechnic Institute of Bragança, Bragança, Portugal.
2 Polytechnic Health Institute of the North – CESPU, Gandra, Portugal.
3 University Veterinary Hospital of Paredes – ONEVET, Paredes, Portugal.
4 Department of Veterinary Sciences, School of Agrarian and Veterinary Sciences – ECAV, University of Trás-os-Montes e Alto Douro – UTAD, Vila Real, Portugal.
5 Animal and Veterinary Research Centre – CECAV, Associate Laboratory for Animal and Veterinary Science – AL4AnimalS, Vila Real, Portugal.

*Correspondent author: a59010@alunos.ipb.pt

[#] These authors contributed equally to this work.

ABSTRACT

Case description: A 5-year-old female French Bulldog was presented with cervical pain and discomfort. At presentation, the patient was ambulatory but showed mild proprioceptive deficits in the right pelvic limb. Radiographs revealed cervical, thoracolumbar and lumbosacral discospondylosis, while the remaining findings were unremarkable. Two days later, a deterioration of the clinical signs was observed. The patient became almost unable to walk, progressing to non-ambulatory tetraparesis. It also showed reluctance to move the neck during flexion, decreased proprioception in all limbs and reduced flexor reflexes in the thoracic limbs. An emergency CT scan revealed an extrusive intervertebral disc herniation (Hansen Type I) at C4–C5, median to right paramedian, occupying approximately 40% of the vertebral canal and causing spinal cord compression, consistent with intervertebral disc disease (IVDD). Emergency surgery was performed successfully. Post-operative treatment included methylprednisolone, dexmedetomidine CRI (to be administered in case of respiratory stress), gabapentin and paracetamol. In addition to pharmacological treatment, a rehabilitation plan was initiated three days later, and the patient was able to stand and walk by the following day. **Discussion:** IVDD is a common neurological condition in chondrodystrophic breeds such as French Bulldogs and may result in pain, reduced mobility and neurological deficits. In the present case, an extrusive disc herniation at C4-C5 caused acute neurological deterioration requiring emergency surgical intervention. Although surgical decompression is essential to relieve spinal cord compression, postoperative management and rehabilitation are fundamental to optimise functional recovery. In this context, veterinary nurses play a key role in implementing rehabilitation protocols and monitoring the patient's clinical progression. Rehabilitation techniques such as passive range-of-motion exercises, assisted walking and proprioceptive stimulation help maintain joint mobility, improve muscle strength and prevent complications associated with immobilisation. This case highlights the importance role of veterinary nursing in postoperative rehabilitation, contributing to neurological recovery and improving the quality of life of dogs affected by IVDD.

Funding
Not applicable.

Conflict of Interest Declaration
The authors declare no conflicts of interest.

PC33 Zoonotic hazards in public spaces: detection of canine gastrointestinal parasites in Arcos de Valdevez

Amaral S.F.[1,2,*], Maroso J.[2], Coelho A.C.[4], Mateus T.L.[2,3,4]

[1] Escola de Ciências Agrárias e Veterinárias, Universidade de Trás-os-Montes e Alto Douro, Vila Real, Portugal.
[2] CISAS – Center for Research and Development in Agrifood Systems and Sustainability, Escola Superior Agrária, Instituto Politécnico de Viana do Castelo, Portugal.
[3] Escola Superior Agrária, Instituto Politécnico de Viana do Castelo, Portugal.
[4] CECAV – Veterinary and Animal Research Centre, UTAD, Associate Laboratory for Animal and Veterinary Sciences (AL4AnimalS), Vila Real, Portugal.

*Correspondent author: sandra.ferrao.amaral@gmail.com

ABSTRACT

Introduction and Aim: Inadequate awareness among dog owners and the presence of free roaming dogs contribute to the widespread deposition of canine faeces in public spaces, posing both aesthetic and public health concerns due to the dissemination of zoonotic agents. This study aimed to evaluate environmental contamination by gastrointestinal parasites in dog faeces collected in Arcos de Valdevez, Portugal. **Materials**

and Methods: Dog faecal samples were collected from green spaces in Arcos de Valdevez between February and March 2026. Samples were identified, refrigerated, and analysed using quantitative coprological examination (Mini Flotac® technique). **Results:** Parasitic forms were identified in 5 of the 63 collected samples (7.9%), namely *Toxocara spp.* and Ancylostomatidae. Two samples (3.2%) contained a single parasite species (one with *Toxocara spp.* and one with Ancylostomatidae), while three samples (4.8%) contained both parasitic forms. The maximum number of eggs per gram (EPG) was 95 (*Toxocara spp.*). **Conclusions:** The presence of *Toxocara spp.* and Ancylostomatidae in public green spaces highlights the persistence of zoonotic parasites in the environment. These parasites can cause gastrointestinal disease, anaemia and poor body condition in dogs, while in humans *Toxocara spp.* may lead to visceral or ocular larva migrans and Ancylostomatidae can cause cutaneous larva migrans. This reinforces the need for improved education on responsible dog ownership to support long term actions within a One Health perspective.

PC34 Environmental contamination with zoonotic parasites from dogs' faeces in public spaces in Ponte de Lima, Portugal

Amaral S.F.[1,2,*], Maroso J.[2], Coelho A.C.[4], Mateus T.L.[2,3,4]

[1] Escola de Ciências Agrárias e Veterinárias, Universidade de Trás-os-Montes e Alto Douro, Vila Real, Portugal.
[2] CISAS – Center for Research and Development in Agrifood Systems and Sustainability, Escola Superior Agrária, Instituto Politécnico de Viana do Castelo, Portugal.
[3] Escola Superior Agrária, Instituto Politécnico de Viana do Castelo, Portugal.
[4] CECAV – Veterinary and Animal Research Centre, UTAD, Associate Laboratory for Animal and Veterinary Sciences (AL4AnimalS), Vila Real, Portugal.

*Correspondent author: sandra.ferrao.amaral@gmail.com

ABSTRACT

Introduction and Aim: Dogs can contaminate public spaces with faeces containing zoonotic parasites, creating a potential public health risk for both people and animals. As Portugal has one of the highest numbers of companion dogs in Europe, this study aimed to assess environmental contamination by gastrointestinal parasites in dog faeces collected in public areas of Ponte de Lima. **Materials and Methods:** Dog faecal samples were collected from public spaces in Ponte de Lima, between February and March 2026. The samples were properly identified and stored under refrigeration until laboratory analysis. A quantitative coprological analysis (Mini Flotac® technique) was performed. **Results:** A total of 54 environmental samples were collected. Parasitic forms were identified in 2 samples (3.7%), namely *Toxocara spp.* and Ancylostomatidae. One sample (1.9%) had only *Toxocara spp.*, and the other (1.9%) had both parasitic forms. The maximum number of eggs per gram (EPG) was 185 (*Toxocara spp.*). **Conclusions:** The overall prevalence of parasitic forms was low. With the expected increase in prevalence during spring, given the zoonotic potential of the parasites identified, which constitute a risk to Public Health, reinforcing responsible dog ownership practices remains essential. The availability of updated epidemiological data, particularly at regional and local levels, is crucial to support effective control strategies and to enhance public awareness.

Funding
The participation of Mateus TL and Coelho AC was funded by national funds through FCT – Fundação para a Ciência e a Tecnologia, I.P. (https://doi.org/10.54499/UID/05937/2025 and https://doi.org/10.54499/UID/00772/2025, respectively).

Conflict of Interest Declaration
The authors declare no conflicts of interest.

PC35 Gastrointestinal parasitic biodiversity of small ruminants in the north of Portugal

Maroso J.C.[1,*], Ruano Z.[2,3], Mateus T.L.[2,3]

[1] Escola Superior Agrária, Instituto Politécnico de Viana do Castelo (IPVC), Viana do Castelo, Portugal
2 CISAS - Escola Superior Agrária, IPVC, Viana do Castelo, Portugal
3 CECAV-UTAD, AL4AnimalS, Vila Real, Portugal.

*Correspondent author: julianamaroso@ipvc.pt

ABSTRACT

Introduction and Aim: Gastrointestinal parasitosis in small ruminants have a recognized impact on the economy, animal and public health. Most studies on these parasitosis take place in farms with a high number of animals. In the north of Portugal it is very common to find farms with few animals, engaged in subsistence farming. The aim of this study was to evaluate the prevalence and diversity of gastrointestinal parasites in small ruminant farms in this region. **Materials and Methods:** Samples were collected from sheep and goat farms in the north of Portugal, namely in Minho and Trás-os-Montes. A qualitative coprological analysis was performed (Willis). **Results:** A total of 148 samples were collected. At least eight different parasites were identified in 85.13% (n=126) of the samples. Strongylids were by far the most frequently identified eggs (93.2%, and within these, 5.4% were *Nematodirus spp.*), followed by Eimeria spp. oocysts (39.2%), Trichuris spp. (10.1%), and then, more residually, the genera *Capillaria*, *Moniezia* and *Dicrocoelium* (2.02% in both), *Skrjabimena* and *Fasciola* (0.9% in both). Of the samples containing parasitic forms, most had more than one distinct parasite, representing double (40.5%), triple (6.8%), or quadruple (3.4%) infections. **Conclusions:** Although the assessment was qualitative, some samples had a very high number of parasitic forms. A quantitative analysis is ongoing. The high prevalence and diversity of parasitic forms identified, particularly the high percentage of multiple infections (50.7%), highlights the great gastrointestinal parasitic biodiversity in these animals, which may not be a bad new in the context of anthelmintic resistance. However, we emphasize the presence of zoonotic parasites such as *Dicrocoelium* and *Fasciola*, highlighting the need to educate these farmers about the risks present on their farms from a One Health perspective.

Funding
This work was funded by national funds through FCT – Fundação para a Ciência e a Tecnologia, I.P. (https://doi.org/10.54499/UID/05937/2025).

Conflict of Interest Declaration
The authors declare no conflicts of interest.

PC36 Biodiversity of gastrointestinal parasites in cattle of native breeds from northern Portugal

Maroso J.C.[1,*], Ruano Z.[2,3], Mateus T.L.[2,3]

[1] Escola Superior Agrária, Instituto Politécnico de Viana do Castelo (IPVC), Viana do Castelo, Portugal
2 CISAS - Escola Superior Agrária, IPVC, Viana do Castelo, Portugal
3 CECAV-UTAD, AL4AnimalS, Vila Real, Portugal.

*Correspondent author: julianamaroso@ipvc.pt

ABSTRACT

Introduction and Aim: Cattle of native breeds from northern Portugal, such as Minhota, Cachena, Barrosã, and Mirandesa, represent an important economic support for farmers, sometimes being their only source of livelihood. Gastrointestinal parasitosis can have serious effects on animal health subsequently impacting the farm's economy. The objective of this study was to assess the prevalence and diversity of gastrointestinal parasites in four different native breeds of cattle in northwestern Portugal. **Materials and Methods:** Samples were collected from cattle farms in the north of Portugal, namely in Minho (municipalities of Ponte de Lima and Arcos de Valdevez) and Trás-os-Montes (municipality of Miranda do Douro). The samples were properly identified and stored under refrigeration until laboratory analysis. A qualitative coprological analysis (Willis method) was performed. **Results:** A total of 77 samples were collected from different native breeds: Minhota (n=25), Cachena (n=24), Barrosã (n=15) and Mirandesa (n=13). At least five different parasites were identified in 25 of 77 samples (32.5%): strongylids (25.9%, among them *Nematodirus sp.*), *Eimeria spp.* (16.9%), *Toxocara vitulorum* (2.6%) and *Moniezia* (1.3%). The presence of parasites was more frequent in Barrosã (66.7%) followed by Cachena (50.0%), and then more residual in Minhota (8.0%) and Mirandesa (7.7%). **Conclusions:** Considering that these animals are grazing animals, the prevalence was low. Although the assessment was qualitative, the burden of parasites seems very low. A quantitative analysis is ongoing. During the sample collection, no animals with symptoms were identified, demonstrating a certain resilience in these animals. In any case, and in order to avoid production losses, it is important to raise awareness among farmers about good management practices and the need to monitor the parasite burden for deworming when necessary.

Funding
This work was funded by national funds through FCT – Fundação para a Ciência e a Tecnologia, I.P. (https://doi.org/10.54499/UID/05937/2025).

Conflict of Interest Declaration
The authors declare no conflicts of interest.

PC37 Gastrointestinal parasites wild ungulates from the north of Portugal

Maroso J.C.[1,*], Mateus T.L.[2,3,4]

[1] Escola Superior Agrária, Instituto Politécnico de Viana do Castelo, Viana do Castelo, Portugal
[2] CISAS - Center for Research and Development in Agrifood Systems and Sustainability, Escola Superior Agrária, Instituto Politécnico de Viana do Castelo, Viana do Castelo, Portugal
[3] Veterinary and Animal Research Centre (CECAV), UTAD, Associate Laboratory for Animal and Veterinary Sciences (AL4AnimalS), Vila Real, Portugal
[4] EPIUnit ITR, Instituto de Saúde Pública da Universidade do Porto, Universidade do Porto Porto, Portugal.

*Correspondent author: julianamaroso@ipvc.pt

ABSTRACT

Introduction and Aim: Wild ungulates like red deer (*Cervus elaphus*) and wild boar (*Sus scrofa*) are very common in the north of Portugal. Wild boar populations are even becoming a problem, partly because of their high adaptability but mainly because of the lack of predators. They all may be carriers of agents with zoonotic potential, so monitoring wild ungulates is important in the context of animal and public health. The aim of this study was to assess the prevalence and diversity of gastrointestinal parasites in these animals. **Materials and Methods:** The samples were collected in hunting activities in the north of Portugal and analyzed by flotation and sedimentation methods. **Results:** A total of 93 (49 from wild boars and 44 from red deer) fecal samples were collected. The prevalence by animal species were 59.2% (29/49) in wild boars (strongylids, 38.8%, *Physocephalus spp.* and *Eimeria spp.*, 8.2% in both, *Macracanthorinchus sp.*, 4.1% and *Trichuris suis*, 2.0%) and 40.9% (18/44) in red deer (strongylids, 34.1%, *Moniezia spp.*, 4.6% and *Eimeria spp.*, 2.3%). **Conclusions:** The prevalences found were high in both species and a higher diversity of parasites was found in wild boars. In wild boars two zoonotic parasites were identified (*Macracanthorhynchus sp.* and *Trichuris suis*) raising awareness on public health. Monitoring wildlife health is crucial for animal, environmental and public health, in a one health perspective.

Funding
This work was funded by national funds through FCT – Fundação para a Ciência e a Tecnologia, I.P. (https://doi.org/10.54499/UID/05937/2025).

Conflict of Interest Declaration
The authors declare no conflicts of interest.

PC38 Coprological approaches for gastrointestinal parasites in wild birds admitted to a wildlife rehabilitation center

Gomes M.[1,2,*], Barradas P.[3,4]

[1] Tâmega and Sousa School of Health Technologies, Cooperativa de Ensino Superior Politécnico e Universitário (IUCS-CESPU), Avenida Central de Gandra 1317, 4585-116 Paredes, Portugal
[2] Parque Biológico de Gaia, Vila Nova de Gaia, Portugal
[3] UCIBIO, Applied Molecular Biosciences Unit, University Institute of Health Sciences, IUCS-CESPU, Rua Central de Gandra, 1317, 4585-116 Gandra PRD, Portugal
[4] CECAV – Veterinary and Animal Research Center, University of Trás-os-Montes e Alto Douro (UTAD), Vila Real 5000-801, Portugal.

*Correspondent author: matildemg13@gmail.com

ABSTRACT

Introduction and Aim: Wildlife rehabilitation centers frequently receive wild birds requiring clinical evaluation and treatment, including parasitological assessment. Coprological analysis is a widely used diagnostic tool in veterinary medicine, particularly due to its non-invasive nature, low cost, and ability to provide valuable information about endoparasites affecting wildlife populations. Furthermore, these analyses can contribute to a better understanding of parasite circulation in natural ecosystems, particularly when the animals admitted to rehabilitation centers originate from free-living populations rather than captive environments. We aimed to describe the coprological diagnostic techniques, gastrointestinal parasites detected, and treatments applied in wild birds admitted to a wildlife rehabilitation center. **Materials and Methods:** In wildlife rehabilitation centers, fecal samples from admitted birds are routinely collected as part of the clinical evaluation and monitoring process. Species frequently admitted include the common buzzard (*Buteo buteo*), black kite (*Milvus migrans*), tawny owl (*Strix aluco*), Wood Pigeon (*Columba palumbus)* and little owl (*Athene Noctua*). Samples were obtained from freshly voided feces or directly from the cloaca using a sterile swab. Fresh samples are preferred whenever possible, as fragile parasitic stages, particularly protozoa, may degrade rapidly under environmental conditions. Coprological examination is commonly performed using two routine diagnostic techniques: direct fecal smear and fecal flotation. The direct fecal smear technique consists of spreading a small amount of fecal material on a microscope slide and adding one or two drops of sodium chloride (NaCl) solution. A coverslip is placed over the preparation, and the sample is immediately examined under an optical microscope. This method allows rapid observation of parasitic stages and is particularly useful for detecting motile protozoa and other delicate structures that may be damaged during concentration procedures. Willis method is a qualitative diagnostic technique commonly used for the detection of parasite eggs, protozoan cysts and oocysts. Approximately 2g of faeces are mixed with a saturated solution and filtered to remove large debris. The suspension is transferred to a container until a convex meniscus forms, after which a coverslip is placed on the surface for approximately 20 minutes. The coverslip is then transferred to a microscope slide for microscopic evaluation. Objectives of 10× and 20× are commonly used for the observation of helminth eggs, including nematodes, trematodes and cestodes, while the 40× objective may be used for improved visualization of protozoan forms. Veterinary nursing professionals assist with sample collection, coprological testing, laboratory procedures, and microscopic examination. **Results:** The most frequently reported endoparasites in wild birds admitted to the rehabilitation center are protozoa of the class Coccidia, particularly of the genus *Eimeria*, and helminths of the class Nematoda, specifically of the genus *Capillaria*. When detected, nematode infections are commonly treated with fenbendazole, whereas coccidial infections are treated with toltrazuril. **Conclusions:** Coprological analysis represents a practical, non-invasive and accessible diagnostic method for detecting gastrointestinal parasites in wild birds admitted to wildlife rehabilitation centers. The routine application of these techniques supports clinical decision-making and highlights the important role of veterinary nursing professionals in the diagnostic and rehabilitation process.

Funding
Not applicable.

Conflict of Interest Declaration
The authors declare no conflict of interest.

PC39 Prevalence of *Oxyuris spp.* in captive reptile species

Rubim A.[1,*,#], Oliveira J.[1,#], Morais E.[1,#], Cardoso L.[2,3], Barradas P.[2,4]

[1] Tâmega and Sousa School of Health Technologies, Cooperativa de Ensino Superior Politécnico e Universitário (IPSN-CESPU), Paredes, Portugal
[2] CECAV – Veterinary and Animal Research Center, University of Trás-os-Montes e Alto Douro (UTAD), Vila Real, Portugal
[3] Associate Laboratory for Animal and Veterinary Sciences, UTAD, Vila Real, Portugal.
[4] UCIBIO, Applied Molecular Biosciences Unit, University Institute of Health Sciences, IUCS-CESPU, Gandra, Portugal.

*Correspondent author: anarubim99@gmail.com

# These authors contributed equally.

ABSTRACT

Introduction and Aim: Parasitic infections represent an important health concern among pet reptiles obtained from captive breeding facilities and pet shops. With the increasing popularity of reptiles as companion animals, understanding the composition and epidemiology of parasites present in captive populations is essential for veterinary practice. *Oxyuris spp.* are gastrointestinal nematodes belonging to the superfamily Oxyuroidea, commonly found in the intestinal lumen of reptiles. These parasites are particularly prevalent in herbivorous lizards and tortoises, where they complete a direct homoxene life cycle, excreting unembryonated eggs in faeces that embryonate in the environment. Although infections with oxyurids are often subclinical and may even facilitate gastrointestinal transit, high parasite burdens can result in clinical manifestations, including anorexia and intussusception. This study aimed to determine the prevalence of *Oxyuris spp.* among different reptile species in a pet shop setting, identify susceptible hosts, and assess the effectiveness of reported deworming protocols. **Materials and Methods:** Faecal samples were collected from 15 reptiles representing twelve different species from a commercial pet shop, all of which had reportedly received anthelmintic treatment according to vendor records. A flotation technique was used as the primary diagnostic method, selected for its high sensitivity in detecting oxyurid eggs and identification of co-infection patterns. Quantitative analysis using the McMaster method was performed specifically for bearded dragons (Pogona vitticeps), as preliminary screening indicated heavy parasite burdens in this species. This quantitative approach enabled the accurate determination of eggs per gram (EPG) and oocysts per gram (OPG) of faeces. **Results:** *Oxyuris spp.* eggs were detected in 67% of reptile species sampled. The highest prevalence was observed in Russian tortoises (*Testudo horsfieldii*) and bearded dragons. Quantitative analysis in bearded dragons (*Pogona vitticeps*) revealed considerable co-infection with *Cystoisospora spp.*, with counts of 7,665 OPG and 450 *Oxyuris spp.* EPG, confirming substantial parasitic loads despite reported deworming. European tortoise (*Geochelone pardalis*) and adult leopard geckos (*Eublepharis macularis*) exhibited more pronounced infection levels, whereas juvenile geckos

conspecifics revealed lower burdens. Red-footed tortoises (*Chelonoidis carbonaria*), sulcata tortoises (*Centrochelys sulcata*), and green iguanas (*Iguana iguana*) exhibited low-grade infections. Marginated tortoises (*Testudo marginata*) and Hermann's tortoises (*Testudo hermanni*) tested negative. Amongst insectivorous species, leopard geckos were positive whilst Yemen chameleons (*Chamaeleo calyptratus*) showed minimal burdens. Strictly carnivorous species, including ball pythons (*Python regius*) and savannah monitors (*Varanus exanthematicus*), tested negative. These findings suggest that host species susceptibility and individual husbandry conditions may influence infection risk beyond dietary category alone. **Conclusions:** *Oxyuris spp.* infection remains highly prevalent in captive herbivorous reptiles. The substantial parasite burdens detected, despite reported anthelmintic treatment, underscore the importance of treatment timing aligned with the parasite life cycle to prevent reinfection from environmental reservoirs. Regular parasitological screening should be standard practice in captive reptile management, particularly for herbivorous species, to prevent clinical disease and optimise animal welfare.

Funding
This work was funded by the University Institute of Health Sciences (IUCS-CESPU, GenRick-GI2-CESPU-2025).

Conflict of Interest Declaration
The authors declare no conflicts of interest.

PC40 Comparative prevalence of Anisakis spp. in selected commercial fish and cephalopods

Silva C.[1,*], Cerqueira F.[1], Fonseca R.[1,#], Marque A.[1], Barradas P.[2,3]

[1] Tâmega and Sousa School of Health Technologies, Cooperativa de Ensino Superior Politécnico e Universitário (IPSN-CESPU), Paredes, Portugal
[2] UCIBIO, Applied Molecular Biosciences Unit, University Institute of Health Sciences, IUCS-CESPU, Paredes, Portugal
[3] CECAV - Veterinary and Animal Research Center, University of Trás-os-Montes e Alto Douro, Vila Real, Portugal.

*Correspondent author: a35576@alunos.cespu.pt

[#] These authors contributed equally to this work.

ABSTRACT

Introduction and Aim: *Anisakiasis* is a zoonosis of growing importance worldwide, particularly due to the increasing popularity of cuisines that use raw or undercooked fish, this work aimed to evaluate and compare the distribution of Anisakis larvae among multiple commercial fish species to identify variations in parasitic infestation. Nematodes of the genus *Anisakis*, represented mainly by the species *Anisakis simplex* and *Pseudoterranova decipiens*, has a complex life cycle involving multiple intermediate and definitive hosts, in some situations may also result in accidental infection of humans. **Materials and Methods:** The methodology consisted of an observational study involving three *Trachurus trachurus*, five *Sardina pilchardus*, ten *Scomber scombrus*, and one *Salmo salar* fillet. Additionally, three Sepia officinalis specimens were included. All samples were collected in November 2024. Parasite isolation was performed through visual inspection followed by manual extraction using forceps. The specimens were examined macroscopically and under a stereomicroscope to assess morphological features. Identification was based on established morphological criteria, including body shape, size, and distinguishing anatomical structures. The anatomical regions analysed included the visceral cavity and muscle tissue, where parasites are most found. **Results:** The presence of *Anisakis spp.* larvae varied among the analysed species. In sardines, only a single larva was detected (1/5), corresponding to a low occurrence. In contrast, all mackerel samples (10/10) were positive for *Anisakis* larvae, indicating a high occurrence in this species. Horse mackerel showed limited parasitic presence, with larvae detected in a minority of samples. No larvae were observed in the analysed salmon fillet. Among cephalopods, *Anisakis* larvae were not detected in the cuttlefish samples examined (0/3). Overall, these findings suggest variability in parasite occurrence across different host species, with higher detection in mackerel compared to other fish analysed. **Conclusions:** The results of this observational study confirmed the presence of *Anisakis spp.* in the analysed samples, particularly in the visceral cavity and muscle tissues of the examined fish species. Variations in parasite occurrence were observed among *Trachurus trachurus*, *Sardina pilchardus*, and *Scomber scombrus*, reinforcing the relevance of species-specific susceptibility. No parasites were detected in the analysed *Salmo salar* fillet, while the examined *Sepia officinalis* specimens did not show evidence of infection. These findings highlight the importance of routine inspection and proper handling of fishery products, especially those intended for raw or undercooked consumption. Public awareness campaigns, combined with good practices in fish processing, remain essential to prevent anisakiasis and ensure food safety. Furthermore, continuous monitoring of *Anisakis* prevalence is crucial to better understand its distribution and to support effective preventive measures aimed at protecting public health.

Funding
Not applicable.

Conflict of Interest Declaration
The authors declare no conflicts of interest.

PC41 Molecular surveillance of *Rickettsia spp.* in stray cats from Viana do Castelo

Teixeira M.[1,#,*], Sousa M.[1,#], Faria A.[1,#], Marques A.[1], Gomes-de-Sá S.[2], Barradas P.[1,3]

[1] Tâmega and Sousa School of Health Technologies, Cooperativa de Ensino Superior Politécnico e Universitário (IUCS-CESPU), Paredes, Portugal
[2] UCIBIO, Applied Molecular Biosciences Unit, University Institute of Health Sciences, IUCS-CESPU, Gandra, Portugal
[3] CECAV - Veterinary and Animal Research Center, University of Trás-os-Montes e Alto Douro, Vila Real, Portugal.

*Correspondent author: a38424@alunos.cespu.pt

[#] All authors contributed equally.

ABSTRACT

Introduction and Aim: Bacteria of the genus Rickettsia are obligate intracellular Gram-negative microorganisms of the order Rickettisiales, characterised by their dependence on the intracellular environment for replication. These bacteria are transmitted primarily by blood-feeding arthropods such as

ticks, fleas, lice and mites, which act as vectors and often also as natural reservoirs of the infectious agent. Environmental and ecological changes have contributed to the geographical expansion of these vectors, favouring the spread of tick-borne diseases in different regions. Stray cats are highly exposed to these ectoparasites, particularly ticks and fleas, due to their outdoor lifestyle and frequent contact with uncontrolled environments. This increased exposure raises the risk of infection by vector-borne pathogens, including Rickettsia spp. This study aimed to investigate the presence of Rickettsia spp. in stray cats in the Viana do Castelo area, enrolled in trap-neuter-return (TNR) programmes. **Materials and Methods:** In this study, 66 samples from cats were analysed. The methodology involved the extraction of genomic DNA using a DNA isolation kit, followed by PCR amplification with primers targeting conserved genes of the genus Rickettsia. The amplified products were subsequently subjected to agarose gel electrophoresis, enabling visualisation of amplified DNA fragments. **Results:** All pools analysed tested negative for the presence of Rickettsia spp. by PCR. **Conclusions:** The absence of positive results suggests that Rickettsia spp. DNA was not detected in the analysed samples. However, these findings may reflect limitations associated with molecular detection in blood samples, such as low bacterial load or transient bacteraemia, potentially leading to an underestimation of the true infection rate. The inclusion of serological testing could complement molecular methods and provide a more comprehensive assessment of Rickettsia spp. circulation in this population.

Funding
Not applicable.

Conflict of Interest Declaration
The authors declare no conflicts of interest.

SPONSORS

SPONSORS

Thank you to all our Sponsors and Partners for their support and for contributing to the success of the 1st International Congress on Veterinary Sciences.

ORGANIZED BY

CESPU COOPERATIVA DE ENSINO SUPERIOR POLITÉCNICO E UNIVERSITÁRIO

CESPU INSTITUTO UNIVERSITÁRIO DE CIÊNCIAS DA SAÚDE

CESPU INSTITUTO POLITÉCNICO DE SAÚDE DO NORTE

SUPPORTED BY

amigosparasempre funerariaanimal

bio2 Grupo AE

BLUE SURGICAL INSTRUMENTS

BSA BANCO SANGUE ANIMAL

Elanco

INCISION

MSD Animal Health

MSO VETERINARIA

onevet

PURINA PRO PLAN

ROYAL CANIN

Servive veterinária Grupo NUZOA

SIEMENS

SOPRO JUNTOS, SOMOS CONFIANÇA

VA Veterinária Atual by Skolae

António Guilherme Oliveira veterinary books phone number: +351 934 800 055 e.mail: antoniogoliveira.medvetbooks@gmail.com

VetNova

zoetis

Univet LES VÉTÉRINAIRES UNIS

In *Scientific Letters*, works are published under a CC-BY license (Creative Commons Attribution 4.0 International License at https://creativecommons.org/licenses/by/4.0/), the most open license available. The users can share (copy and redistribute the material in any medium or format) and adapt (remix, transform, and build upon the material for any purpose, even commercially), as long as they give appropriate credit, provide a link to the license, and indicate if changes were made (read the full text of the license terms and conditions of use at https://creativecommons.org/licenses/by/4.0/legalcode).

Volume 1 Supplement 2 (2026)

ISSN 2795-5117

CESPU INSTITUTO UNIVERSITÁRIO DE CIÊNCIAS DA SAÚDE

CESPU INSTITUTO POLITÉCNICO DE SAÚDE DO NORTE
POLYTECHNIC UNIVERSITY OF HEALTH

FARM4FUTURE PRR REPÚBLICA PORTUGUESA Financiado pela União Europeia

Scientific Letters

CESPU University Publishing | https://publicacoes.cespu.pt/index.php/sl/